

The Journal of Phytopharmacology

(Pharmacognosy and phytomedicine Research)

Research Article

ISSN 2320-480X

JPHYTO 2022; 11(2): 57-59

March- April

Received: 03-02-2022

Accepted: 12-03-2022

©2022, All rights reserved

doi: 10.31254/phyto.2022.11201

Sunil Hajare

Post Graduate Institute of Veterinary and Animal Sciences (PGIVAS), Akola - 444104, Maharashtra, India

Ranjit Suresh Ingole

Post Graduate Institute of Veterinary and Animal Sciences (PGIVAS), Akola - 444104, Maharashtra, India

Mahesh Kumar

Post Graduate Institute of Veterinary and Animal Sciences (PGIVAS), Akola - 444104, Maharashtra, India

Vitthal Ingawale

Assistant Professor, Department of Post Graduate Institute of Veterinary and Animal Sciences (PGIVAS), Akola-444104, Maharashtra, India

Vivek Borekar

Post Graduate Institute of Veterinary and Animal Sciences (PGIVAS), Akola - 444104, Maharashtra, India

David Kumar

Research and Development Unit, Ayurved Limited, Baddi-173205, Himachal Pradesh, India

Bhaskar Ganguly

Research and Development Unit, Ayurved Limited, Baddi-173205, Himachal Pradesh, India

Correspondence:

Dr. David Kumar

Research and Development Unit, Ayurved Limited, Baddi-173205, Himachal Pradesh, India
Email: clinical01@ayurved.in

Evaluation of acute dermal toxicity of a topical anti-mastitis gel

Sunil Hajare, Ranjit Suresh Ingole, Mahesh Kumar, Vitthal Ingawale, Vivek Borekar, David Kumar, Bhaskar Ganguly

ABSTRACT

This study was undertaken to evaluate the acute dermal toxicity of a topical anti-mastitis gel (Mastilep® gel; M/s Ayurved Limited, India) in accordance with OECD 402 guidelines. Nine adults female Wistar rats, weighing 210-250 g, were used in the study. Following the topical application of the anti-mastitis gel, the animals were observed for the manifestation of toxic effects and mortality. Toxicity was evaluated on the basis of changes in body weight, histological appearances of heart, liver, kidney, and lungs, and blood biochemical parameters viz. AST, ALT, ALP and creatinine. Since no toxic effects or deaths were recorded until completion of the experiment, the anti-mastitis gel was found safe for dermal use.

Keywords: Topical, Anti-mastitis gel, Safety, Acute dermal toxicity, OECD 402, Mastilep® gel.

INTRODUCTION

Mastitis, an inflammation of the mammary gland, is the most common disease of dairy cattle, causing economic losses due to reduced milk yield and poor quality of milk [1]. Mastitis can be clinical or subclinical; both forms produce significant economic losses due to less production, degraded milk quality, early culling of cows, medicine costs, and veterinary expenses [2]. The use of herbal medicine has been reported to successfully maintain the udder hygiene score with added benefits of safety, efficacy, and cost-efficiency [3].

Mastilep® gel (M/s Ayurved Limited, India) is a non-antibiotic polyherbal gel for topical application on udder and teats for treatment and prevention of mastitis. It functions as a non-irritant protective emollient, checks growth of microorganisms, and maintains hygiene, health, and productivity of the mammary gland when applied during different stages of lactation. The constituent herbal ingredients of Mastilep® gel viz. *Cedrus deodara*, *Curcuma longa*, *Glycyrrhiza glabra*, and *Eucalyptus globulus* are well-proven in alternative medicine for their antibacterial, anti-inflammatory, analgesic and anti-histaminic, and immunomodulatory properties [4-6]. The goal of this study was to determine the acute dermal toxicity potential of Mastilep® gel.

MATERIALS AND METHODS

The study was performed at the Department of Veterinary Pharmacology and Toxicology at the Post Graduate Institute of Veterinary and Animal Sciences (PGIVAS), Akola, India. The Institutional Animal Ethics Committee (IAEC) of PGIVAS, Akola approved the trial protocol (approval number 312/4/15/2000/20; dated 06.03.2020).

Nine adult Wistar rats of 8-10 weeks of age (210 - 250 g) were used. The animals were obtained from the animal resource section, National Institute of Biosciences, Pune. IAEC SOPs and CPCSEA regulations were followed for all animals. Picric acid staining was used for animal identification. The number of animals per cage was limited to three for simple monitoring and adequate housing facilities were provided. However, animals were kept individually for first 24 h of treatment. The animals were subjected to a 12 h light and dark cycle with constant temperature (25±2 °C) and relative humidity (70%). The animals were fed a conventional pelleted feed and had access to ample water [7].

In accordance with OECD 402 guidelines [7], the animals were housed in cages for five days to adapt to the laboratory environment. Thereafter, the animals were fasted for three to four hours without food or water. After the fasting period, the animals were weighed and the test substance was applied topically. The three rats of Group I were applied with the test substance at a dose of 200 mg/Kg body weight on the dorsum, covering not less than 10% of total body area. If no evidence of toxicity was seen in Group I, the other six rats of Group II were applied with the maximum dose of the test substance, which was

2000 mg/Kg of body weight. In both groups, feeding was withheld for 1-2 h after the application of the test substance. During the 24 h exposure period, animals were caged individually in order to avoid oral ingestion of the test substance by other animals. The test substance was held in contact with the skin throughout the 24 h exposure period by a porous gauze dressing of muslin cloth. The test site was further covered to retain the gauze in place and ensure that the animals did not ingest the test substance.

Animals were monitored for toxic effects and mortality continuously for at least 30 minutes, frequently for the first 24 h, and intermittently thereafter for a total of 14 days. Changes occurring in the eyes and mucous membranes, skin and fur, the respiratory, circulatory, and central nervous systems, autonomic and somatic activity, and behavior patterns, if any, were noted. Muscle tremors, lethargy, diarrhea, salivation, convulsions, irritation, sleep and coma were also noted. After 14 days of observation, animals were euthanized, necropsy was done, and histological examinations of the heart, liver, lungs and kidneys were performed. Biochemical markers viz. aspartate aminotransferase (AST), alanine transaminase (ALT), alkaline phosphatase (ALP), and creatinine were measured in the blood serum. The data of biochemical parameters were examined using one-way ANOVA and a complete randomized design.

RESULTS AND DISCUSSION

The body weights of rats were recorded separately on days 0, 7, and 14 of the study. Body weights of both groups (I and II) continued to increase (Table 1) during the study period. After topical application of the anti-mastitis gel (Mastilep® gel) at 200 mg/Kg b.wt., and 2000

mg/Kg b.wt. to the rats of groups I and II, respectively, no mortality or abnormal signs were observed. The LD₅₀ of anti-mastitis gel was greater than 2000 mg/Kg as no mortality was observed at this threshold dose, which is the maximum dose that can be applied topically.

The organs viz. liver, heart, lungs and kidneys showed no significant changes in appearance at necropsy after 14 days. No histological abnormalities of the liver, heart, lungs and kidneys could be observed in any of the rats either (Figure 1). While the values of ALT in blood serum differed significantly in both groups (Table 2), the results were well within normal ranges, indicating no liver or kidney damage.

Mastilep® gel is prepared from herbal extracts of *Cedrus deodara*, *Curcuma longa*, *Glycyrrhiza glabra* and *Eucalyptus globulus* that belong to the Generally Regarded as Safe (GRAS) category. These herbal extracts have prominent antibacterial, anti-inflammatory, analgesic, antihistaminic and immunomodulatory effects [8-10]. Digraaskar *et al.* [11] achieved remarkable (83.33%) efficacy clinical mastitis in goats by topical application of Mastilep® gel and, further, concluded that Mastilep® gel along with suitable antibiotics is highly efficacious and good therapy against clinical mastitis in goats. Similarly, Hadiya *et al.* [12] evaluated the efficacy of Mastilep® gel instead of using antibiotics as a dry cow therapy and reported that the overall somatic cell count was reduced from 1.87×10⁵ on day 0 to 1.47×10⁵ on day 3 after parturition. Gatne *et al.* [13] evaluated the acute dermal irritation of Mastilep® gel in rabbits and also found an absence of skin lesions or irritation potential.

Table 1: Individual weekly body weights and mortality of experimental rats treated with Mastilep® gel

Dose	Animal No.	Body Weight (g) on day			Mortality
		0	7	14	
(Group I) Mastilep® gel 200 mg/Kg topically	1	216	221	225	No
	2	229	234	238	No
	3	236	239	244	No
	Mean±SE	227.0±5.87	231.33±5.37	235.67±5.61	-
(Group II) Mastilep® gel 2000 mg/Kg topically	1	210	214	218	No
	2	221	224	229	No
	3	226	229	234	No
	4	228	230	234	No
	5	236	238	243	No
	6	248	250	354	No
Mean±SE	228.17±5.3	230.83±5.01	235.33±5.01	-	

Table 2: Mean ± SD values of AST, ALT, ALP and creatinine values in experimental rats

Dose	AST (U/L)	ALT (U/L)	ALP (U/L)	Creatinine (mg/dL)
(Group I) Mastilep® gel 200 mg/Kg b. wt. topically	57.06±4.68	28.19±1.87 ^b	40.08±3.91	0.49±0.066
(Group II) Mastilep® gel 2000 mg/Kg b. wt. topically	68.52±6.66	38.97±1.80 ^a	54.60±3.48	0.82±0.180

a- b values bearing different superscripts differ significantly within columns (p<0.05)

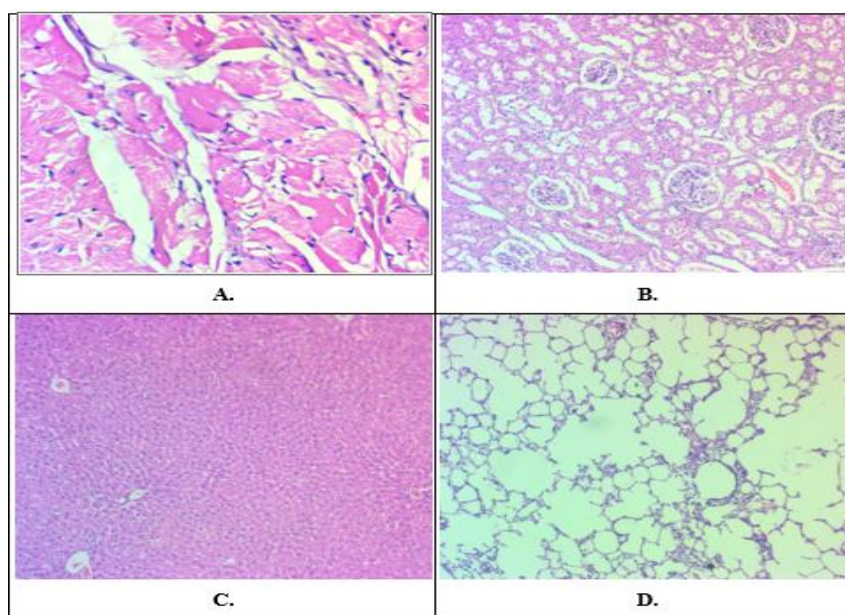


Figure 1: Histological observation of A. heart, B. kidneys, C. liver and D. lungs of rats receiving topical application with Mastilep® gel @ 2000 mg/Kg of b. wt.

CONCLUSION

The present study revealed that the anti-mastitis gel, Mastilep® gel (M/s Ayurvet Limited, India), did not elicit acute dermal toxicity, even when applied at the maximum limit dose (2000 mg/Kg of b.wt.) in rats, as evident from the lack of death, clinical toxicity, and gross or histological changes. Based on these findings, it was concluded that Mastilep® gel is safe for topical use and can be used to treat mastitis without exerting any toxic effects.

Acknowledgments

The authors are grateful to M/s Ayurvet Limited, Baddi, India, for providing financial support.

Conflict of Interest

None declared.

REFERENCES

- Cheng WN, and Han SG. Bovine mastitis: risk factors, therapeutic strategies, and alternative treatments. A review. *Asian-Australasian Journal of Animal Sciences*. 2020;33(11):1699.
- Gruet P, Maincent P, Berthelot X, and Kaltsatos V. Bovine mastitis and intramammary drug delivery: review and perspectives. *Advanced drug delivery reviews*. 2001;50(3):245-59.
- Buragohain J, and Dutta GN. Evaluation of an externally applied herbal gel, AV/AMP/14, for the treatment of bovine subclinical mastitis. *Indian veterinary journal*. 1998;75(8):734-35.
- Akamatsu H, Komura J, Asada Y, and Niwa Y. Mechanism of anti-inflammatory action of glycyrrhizin: effect on neutrophil functions including reactive oxygen species generation. *Planta medica*. 1991;57(02):119-21.
- Ammon HP, Safayhi H, Mack T, and Sabieraj J. Mechanism of anti-inflammatory actions of curcumin and boswellic acids. *Journal of ethnopharmacology*. 1993; 38(2-3):105-12.
- Thakur RS, Puri HS, and Husain A. *Major medicinal plants of India*. Central Institute of medicinal and aromatic plants; 1989.
- No. OECD Test 402: Acute dermal toxicity-fixed dose procedure. OECD guidelines for the testing of chemicals (section 4: health effects). 2017;p. 1-13.
- Bagad AS, Joseph JA, Bhaskaran N, Agarwal A. Comparative evaluation of anti-inflammatory activity of curcuminoids, turmerones, and aqueous extract of curcuma longa. *Advances in Pharmacological Sciences*. 2013. Article ID. 2013;805756.
- Shinde UA, Phadke AS, Nair AM, Mungantiwar AA, Dikshit VJ, and Saraf MN, *et al*. Studies on the anti-inflammatory and analgesic activity of Cedrus deodara (Roxb.) Loud. wood oil. *Journal of Ethnopharmacology*. 1999;65(1):21-27.
- Silva J, Abebe W, Sousa SM, Duarte VG, Machado MI, and Matos FJ, *et al*. Analgesic and anti-inflammatory effects of essential oils of Eucalyptus. *Journal of ethnopharmacology*. 2003;89(2-3):277-83.
- Digraskar SU, Muley VD, Maini S, and Ravikanth K. Therapeutic efficacy of polyherbal gel (Mastilep gel®) and antioxidant-mineral formulation (Uniselit®) against clinical mastitis in goats. *Veterinary Practitioner*. 2011;12(1):128-30.
- Hadiya K, Yadav V, Borthakur A, K Ravikanth, and Maini S. Efficacy of herbal remedies as alternative to antibiotics in dry cow therapy. *World Journal of Pharmaceutical Research*. 2015;6(5):675-80.
- Gatne MM, Tambe K, and Ravikanth K. Acute dermal irritation study of polyherbal gel Mastilep in rabbits. *International Journal of Pharmaceutical Sciences and Research*. 2015;6(8): 3473-76.

HOW TO CITE THIS ARTICLE

Hajare S, Ingole RS, Mahesh Kumar, Ingawale V, Borekar V, Kumar D, Ganguly B. Evaluation of acute dermal toxicity of a topical anti-mastitis gel. *J Phytopharmacol* 2022; 11(2):57-59. doi: 10.31254/phyto.2022.11201

Creative Commons (CC) License-

This article is an open access article distributed under the terms and conditions of the Creative Commons Attribution (CC BY 4.0) license. This license permits unrestricted use, distribution, and reproduction in any medium, provided the original author and source are credited. (<http://creativecommons.org/licenses/by/4.0/>).