

The Journal of Phytopharmacology

(Pharmacognosy and phytomedicine Research)

Research Article

ISSN 2230-480X
JPHYTO 2014; 3(2): 118-123
March-April
© 2014, All rights reserved

Adewale O.B

Department of Biochemistry,
College of Science, Afe Babalola
University, Ado-Ekiti, Ekiti State,
Nigeria

Adekeye A.O

Department of Anatomy, College of
Medicine and Health Sciences, Afe
Babalola University, Ado-Ekiti,
Ekiti State, Nigeria

Akintayo C.O

Department of Physiology, College
of Medicine and Health Sciences,
Afe Babalola University, Ado-Ekiti,
Ekiti State, Nigeria

Onikanni A

Department of Biochemistry,
College of Science, Afe Babalola
University, Ado-Ekiti, Ekiti State,
Nigeria

Sabiu Saheed

Department of Biotechnology and
Molecular Biology, Faculty of Pure
and Applied Sciences, Kwara State
University, Ilorin, Nigeria

Correspondence:

Adekeye A.O

Department of Anatomy, College
of Medicine and Health Sciences,
Afe Babalola University, Ado-
Ekiti, Ekiti State, Nigeria

Tel: +2348038571625

E-mail: cyberdex21@gmail.com

Carbon tetrachloride (CCl₄)-induced hepatic damage in experimental Sprague Dawley rats: Antioxidant potential of *Xylopia aethiopica*

Adewale O.B, Adekeye A.O*, Akintayo C.O, Onikanni A, Sabiu Saheed

Abstract

The present study was carried out to evaluate the hepatoprotective effects of aqueous extract of *Xylopia aethiopica* stem bark (XASB) on carbon tetrachloride (CCl₄) induced liver damage in sprague dawley rats. Experimental rats were randomly divided into four groups of five rats each. Group 1: served as the control rats, Group 2: was administered with CCl₄ only in groundnut oil (1:1) at a dose of 3 ml/kg b.wt by single intraperitoneal administration. Group 3: was administered with extract of *X. aethiopica* + CCl₄ (250 mg/kg b.wt/day), Group 4: was treated with extract of *X. aethiopica* + CCl₄ (500 mg/kg b.wt/day). Serum alanine transferase (ALT), aspartate amino transferase (AST) and alkaline phosphatase (ALP) levels 24 hrs after CCl₄ administration decreased significantly ($p \leq 0.05$) in rats pretreated with *X. aethiopica* than in CCl₄-treated rat only. Total serum bilirubin also showed a remarkable decrease in rats pretreated with *xylopia aethiopica* when compared to those administered with CCl₄ alone. The activities of GST and CAT in liver tissues were increased in the rats pretreated with *X. aethiopica* compared with CCl₄ alone. Lipid peroxidation expressed by malondialdehyde (MDA) concentration was significantly decreased ($p \leq 0.05$) in rats pretreated with *X. aethiopica* compared with CCl₄ treated rat. However, the rats pretreated with *X. aethiopica* showed significant improvements in the cytoarchitecture of rat liver. The results suggested that aqueous extract of *X. aethiopica* could palliate the liver injuries perhaps by its antioxidative effect, hence eliminating the deleterious effect of toxic metabolites from the CCl₄.

Keywords: Oxidative stress, Liver, CCl₄, *Xylopia aethiopica* and Antioxidant enzymes.

Introduction

Oxidative stress is a redox disequilibrium in which the pro-oxidant/antioxidant balance is shifted in favour of the pro-oxidants¹, a phenomenon related to the aerobic nature of cellular metabolism, in which O₂ reduction is a major event. The latter proceeds through electron transfer reactions due to the electronic structure of O₂ in the ground state, with generation of reactive oxygen species (ROS), including Primary oxidants such as superoxide radical (O₂^{•-}), hydrogen peroxide (H₂O₂), and hydroxyl radical (HO⁻) and secondary oxidants such as hydroperoxides and peroxy radicals of biomolecules, in addition to electronically excited states derived from free radical reactions.² The detoxication of ROS is a major requirement of aerobic life¹, which accomplished via several enzymatic and non-enzymatic antioxidant mechanisms that are available in different cell compartments. CCl₄ is a well known hepatotoxic industrial solvent.^{3,4}

CCl_4 is commonly used for free radical induced liver injury.⁵⁻⁷ Liver is not the only target organ of CCl_4 but it also affects several organs of the body such as lungs, hearts, testes, kidneys and brain.⁸ It was reported from the investigation carried out on animal models of acute CCl_4 induced liver damage, It is now generally accepted that CCl_4 toxicity results from bioactivation of CCl_4 into trichloromethyl free radical by cytochrome P450 system in liver microsomes and consequently causes lipid peroxidation of membranes that leads to liver .^{6,9}

However, the cellular antioxidant action is reinforced by the presence of dietary antioxidants.^{10,11} Antioxidants and anti-inflammatory agents play a critical role against CCl_4 intoxication by scavenging active oxygen and free radicals and neutralizing lipid peroxides.¹²

X. aethiopica is a medicinal plant of great repute in Africa which produces a variety of complex chemical compounds and can also be use as spice.^{13,14} Medicinal plants are of great importance to the health of individuals and communities.¹⁵ Due to factors such as poverty and illiteracy that still militate against availability and accessibility of conventional medical services to populace. A larger number of these tropical plants and their extract have shown beneficial therapeutic effects including fertility enhancing and contraceptive compounds, antioxidant, anti-inflammatory, anti-cancer, anti-microbial and aphrodisiac. Among the promising medicinal plants, *X. aethiopica* also known as Negro pepper or Africa pepper are commonly used in Ghana, Nigeria and Cameroon as spices. Despite frequent and regular use, there is no reported work to examine its effect on damage caused by industrial toxicant such as CCl_4 . The study was thus intended to bridge the gap in our continued efforts to establish the effects of local food spices and medications (*X. aethiopica*) on CCl_4 -induced liver damage.

Materials and Methods

Preparations of the aqueous extract of *Xylopia aethiopica* stem bark

The stem bark of *X. aethiopica* was purchased from the Ado-Ekiti market and brought to department of biological sciences for botanical confirmation. The stem bark were freed of extraneous materials, air dried at room temperature and grounded into a uniform powdery form using a milling machine. 20 g of the powdered stem bark of *X. aethiopica* was weighed into 250 ml conical flask.

150 ml of distilled water was added to the sample in the flask. The solution was then stirred with a glass rod and allowed to soak for 24 hrs. The aqueous extract was filtered thrice through a plug of adsorbent cotton wool embedded in a glass funnel. The filtrate was then filtered through 11 cm Round-filter paper. The solution was concentrated by gentle evaporation on a heating mantle and poured into 100 ml beaker.

Chemicals

Carbon tetrachloride was purchased from Sigma, Aldrich (USA).

Experimental animals

Twenty adult male Sprague dawley rats weighing between 150 to 170 g were purchased from the Department of Biochemistry, College of Sciences, Afe Babalola University, Ado-Ekiti. The animals were handled humanely, kept in a plastic suspended cage placed in a well ventilated and hygienic rat house under suitable conditions of temperature and humidity. They were provided with rat pellets, and water ad libitum and subjected to natural photoperiod of 12 hrs light and 12 hrs dark cycle. All experiments were carried out in accordance with research protocols established by the animal care committee of the Afe Babalola Research center, Ado-Ekiti.

Experimental protocol

Animals were divided into four groups of five rats each. Group one serves as control; animals of this group were fed with pellets and water ad libitum for 21 days. Group two (5 rats/group) were administered with CCl_4 only (3 ml/kg body weight of 50% dissolved in groundnut oil) for one day. Group three and four rats were given 250 and 500 mg/kg body weight of *X. aethiopica* stem bark for twenty days followed by CCl_4 for 1 day respectively. All animals were sacrificed by cervical dislocation at the end of twenty first day of the treatment after being fasted overnight.

Induction of hepatic injury

Carbon tetrachloride (CCl_4)-induced liver damage was achieved by injecting 3 ml/kg of CCl_4 intraperitoneally on the twenty first day of feeding the animals in groups 2 to 4 with aqueous extract of *X. aethiopica*.

Tissue preparation for biochemical analysis

The animals (control and CCl₄ treated) were fasted overnight, weighed and sacrificed by cervical dislocation 12h after treatment. Blood sample was collected from the heart vessels into the non-heparinized bottles for serum enzymes analyses, using standard assay kits (Randox Lab Ltd. UK) and the target organ (liver) was quickly excised from each rat. Each organ was separately washed in ice-cold 1.15% KCl solution, blotted and weighed. Each organ from different rats was separately homogenized in a volume of the homogenizing buffer (ice-cold Tris-HCl buffer, 0.1 M, PH 7.4) four times its weight, using a potter Elvehjem type homogenizer. The resulting homogenate in each case was centrifuged at 3000 rpm for 15 minutes at 4°C and the resultant supernatant was used for different oxidative stress markers.

Enzyme analysis

Oxidative stress markers were detected in the resultant supernatant of liver homogenate and hemolysate. The appropriate kits (Biodiagnostic kits) were used for determination of the activity of glutathione-S-transferase (GST)³³ and catalase activity (CAT)³¹, lipid peroxidation in liver homogenates was estimated spectrophotometrically by estimating malondialdehyde levels (MDA).³⁴

Histological procedure

Table 1: Effect of *X. aethiopica* (XA) on liver enzymes and serum bilirubin concentration in experimental treated rats

Group	Treatment	ALP (μ/L)	AST (μ/L)	ALT (μ/L)	Bilirubin mg d/L
1	Control	94.5±0.01	144.2±0.02	56.9±0.07	0.33±0.02
2	CCl ₄ (3 ml/kg bw)	211.7±0.01*	219±0.01*	131.2±0.12*	1.60±0.01*
3	XA(250 mg/kg bw) + CCl ₄	147.2±0.01*#	153±0.021*#	60.33±.21*#	0.35±0.03*#
4	XA(500 mg/kg bw) + CCl ₄	143.4±0.21*#	149±0.02*#	58.1±0.42*#	0.34±0.02*#

Values are expressed as mean ± standard error of mean, n = 5 rats in each group. * = significant increase at p<0.05 compare with control. *# = significant difference at p<0.05 compare with CCl₄ treated rats

Table 2: Effect of *X. aethiopica* (XA) on Lipid peroxidation and antioxidant enzymes in experimental treated rats

Group	Treatment	MDA μmol/L	GST μ/L	CAT μ/L
1	Control	0.62±0.07	0.16±0.05	1.01±0.21
2	CCl ₄ (3 ml/kg bw)	2.62±0.08*	0.05±0.01*	0.65±0.09*
3	XA(250 mg/kg bw) + CCl ₄	1.55±0.40*#	0.70±0.02*#	1.73±.0.02*#
4	XA(500 mg/kg bw) + CCl ₄	1.40±0.03*#	0.73±0.03*#	1.75±0.01*#

Values are expressed as mean ± standard error of mean, n = 5 rats in each group. * = significant difference at p<0.05 compare with control. *# = significant difference at p<0.05 compare with CCl₄ treated rats.

Liver was removed and fixed in Boiuns fluid, dehydrated, cleared, embedded in paraffin wax and cut into 4-5um thick section, then stained specially with Masson trichrome and routinely with hematoxylin and Eosin.

Statistical analysis

All values were expressed as mean±SEM. To evaluate differences between the studied groups, statistical analysis was carried out using the one-way analysis of variance (ANOVA), with LSD post hoc test to compare group mean and P<0.05 was considered statistically significant.

Results and Discussion

The results of hepatoprotective effects of *Xylopi* *aethiopica* stem bark aqueous extract on rats treated with single dose of CCl₄ (3 mL/kg b.wt) are as shown above (Table 1 and 2). The results indicate that rats administered with 3 ml /kg b.wt CCl₄ recorded severe hepatic damage (group 2) when compared to control (group 1) and rats pretreated with *X. aethiopica* (group 3 and 4) respectively. This was evidenced by a marked increase in the levels of serum liver enzymes, (AST, ALT and ALP) in rats treated with CCl₄ alone.

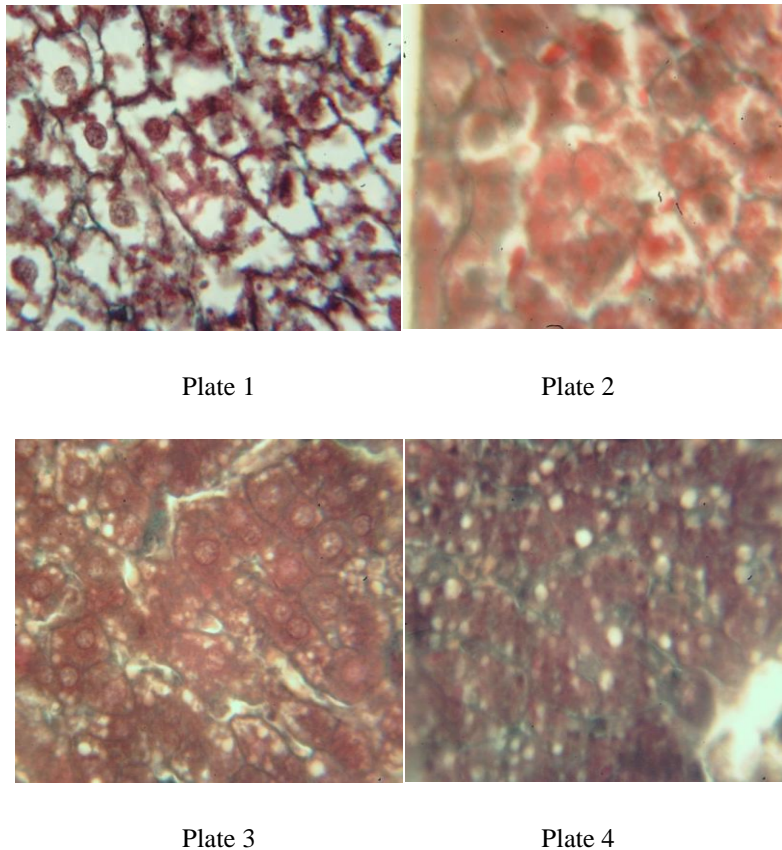


Figure 1: *Plate 1:* Control rat showing normal hepatocytes and collagen fibers; *Plate 2:* Group 2 CCl₄ (3 ml/kg bw) showing vacuolation, fragmented cells, congested central vein; *Plate 3:* Group 3 XA (250 mg/kg bw) + CCl₄ (3 ml/kg bw) showing intact with intact collagen fibers; *Plate 4:* Group 4 XA(500 mg/kg bw) + CCl₄ (3 ml/kg bw) presence of normal hepatic cords, absence of necrosis and lesser fatty infiltration

The marker serum enzymes AST and ALT recorded the lowest value in the group pretreated with *X. aethiopica*. However, the serum ALP was critically observed to be highest in rats pretreated with *X. aethiopica* but the value of GST, CAT, and MDA were not statistically significant when compared with the control group.

The efficacy of any hepatoprotective drug is indeed dependent on its capability of either reducing the harmful effects or in maintaining the normal hepatic physiological mechanism which have been imbalanced by a hepatotoxin. The remarkable elevation in the rats marker enzyme and bilirubin in CCl₄ administered rats in this study is only a confirmation of previous reports on the hepatotoxicity of CCl₄.¹⁷ In fact, in most experiment involving the induction of liver injury in experimental animals, administration of CCl₄ elicited the elevation in the levels of liver marker enzymes (AST, ALT, and ALP) and bilirubin resulting in a significant hepatic damage. The elevated levels of these biochemical parameters are direct reflection of alterations in the hepatic structural integrity.

The results of marker enzymes (histochemistry) levels in rats administered with CCl₄ alone validates those of other markers¹⁸⁻²⁰ who reported elevated levels in the serum contents of hepatic enzymes in rats administered with CCl₄ alone. The elevation of marker enzymes in rats administered with CCl₄ alone reported in this study is the same to the findings of Prakash²⁸ who observed significant hepatic damage in rats treated with single dose of CCl₄ from a SGOT and SGPT.

This is indicative of cellular leakage and loss of functional integrity in liver. In particular, the increase in the serum level of ALT is indicative of liver damage. These enzymes are located in the cell cytoplasm and are emptied into the circulation once the cellular membrane is damaged.²⁴

However, the reduction in the levels of marker enzymes ALT and AST in rats pretreated with *X. aethiopica* stem bark extract as reported in this study is also in agreement with the commonly accepted view that serum levels of transaminases return to normal with healing hepatic parenchyma and the regeneration of hepatocytes. It is evident that an increase in bilirubin concentration in the

serum or tissue is indicative of obstruction in the excretion of bile. Thus, the increased level of bilirubin observed in rats administered with CCl₄ alone (group 2) could be attributed to liver damage. However, the decrease in bilirubin levels in pretreated rats is indicative of reversal of liver damage by the spice.

Administration of 0.5 ml/kg b.wt of CCl₄ has been reported to elevate malondialdehyde (MDA), a product of lipid peroxidation in liver of rats treated with CCl₄ only.^{20,22} They attributed the increase in MDA levels to enhanced lipid peroxidation, leading to tissue damage and failure of antioxidant defense mechanisms to prevent the formation of excessive free radicals. This in turn alters the ratio of polyunsaturated to other fatty acids, thus, leading to a decrease in the membrane fluidity which may be sufficient to cause cell death.²³ The results in this study suggest that pretreatment of rats for 21 days with *X. aethiopica* stem bark extract at varying dosages to CCl₄ administration significantly (P<0.05) reversed these changes. It would be deduced, therefore, that the antioxidant effects of *X. aethiopica* extract could possibly be its mechanism of hepatoprotection.

Histopathological examinations showed defect ranging from massive tissue necrosis, congested central vein, fatty degeneration and infiltration by inflammatory cells in rats treated with CCl₄ alone Figure 1 (Plate 2). However, histological profile of rats pretreated with *X. aethiopica* exhibited significant liver protection against the toxicant as evidenced by the presence of normal hepatic cords, absence of necrosis and lesser fatty infiltration Figure 1 (plate 3 and 4).

Histopathological examination of control rats however, revealed normal architecture Figure 1 (Plate 1). The marked decrease in the levels of serum marker enzymes and MDA in pretreated rats are indications of the ability of *X. aethiopica* stem bark extract to protect the liver against CCl₄ poisoning. This is validated by the cytoarchitecture of the liver of rats that received *X. aethiopica* extract prior to CCl₄ administration.

The findings in this study indicate that pretreatment of rats with *X. aethiopica* stem bark extract 21 days prior to CCl₄ administration caused a marked decrease in the levels of hepato specific serum enzymes. It thus implies that *X. aethiopica* may be protective against CCl₄-induced liver damage in rats.

Conclusion

In conclusion, the results of the present study showed that aqueous extract of *X. aethiopica* stem bark has antioxidant and scavenging activities as it ameliorated the effects produced by CCl₄ in the experimental rats. However, treatment with *X. aethiopica* in liver complicated disease may be of benefit. Further study will investigate on the active principles of *X. aethiopica* and its mechanism of action.

Acknowledgement

The Authors acknowledge the Afe Babalola University for providing facilities to carry out this study.

References

1. Sies, H. Biochemistry of oxidative stress. *Angew. Chem. Int. Engl.*, 1986; 25:1058-1071.
2. Videla LA, Fernandez V. Biochemical aspects of cellular oxidative stress. *Arch Biol. Med Exp. (Santiago)*, 1988; 21:85-92.
3. Abraham P, Wilfred G, Gathrine SP. Oxidative damage to the lipids and proteins of the lungs, testis and kidney of rats during carbon tetrachloride intoxication. *Clin. Chem. Acta*, 1999; 289:177-179.
4. Guven A, Gumez M. The effect of kefir on the activities of GSH-Px, GST, CAT, GSH and LPO levels in carbon tetrachloride-induced mice tissues. *J.Vet.Med. B.Infect.Dis. Vet. Public Health*, 2003; 50:412-416.
5. Junnila M, Rahko T, Sukura A, Lindberg LA. Reduction of carbon tetrachloride-induced hepatotoxic effect by oral administration of betaine in male wistar rats: a morphometric histologic study. *Vet. Pathol.*, 2000; 37(3): 231-238.
6. Cui CP, Wei P, Liu Y, Zhang DJ, Wang LS, Wu CT. The protective role of hepatopietin on liver injury induced by carbon tetrachloride in rats. *Hepatol. Res.*, 2009; 39(2):200-206.
7. Kim HY, Kim JK, Choi JH, Jung JY, Oh WY, Kim DC, Lee HS, Kim YS, Kang SS, Lee SH, Lee SM. Hepatoprotective effect of pinoresinol on carbon tetrachloride-induced hepatic damage in mice. *J. pharmacol. Sci.*, 2010; 112(1): 105-112.
8. Ozturk F, Ucar M, Ozturk IC, Vardi N, Batcioglu K. Carbon tetrachloride-induced nephrotoxicity and protective effect of betaine in Sprague-Dawley rats. *Urology.*, 2003; 62(2):353-356.

9. Ohata Y, Ohashi K, Matsura T, Tokunaga K, Kitagawa A, Yamada K. Octacosanol attenuates disrupted hepatic reactive oxygen species metabolism associated with acute liver injury progression in rats intoxicated with carbon tetrachloride. *J. Clin. Biochem. Nutr.*, 2008; 42(2): 118-125.
10. Kenan CY, Bulbuloglu E. Improved preservation of erythrocyte antioxidant capacity with ascorbic acid reperfusion after ischemia: a comparative study in rat hind limb model. *Int. J. Altern. Med.*, 2005; 2:1.
11. Ghandrasena LG, Chackrewarthy S, Perera PT, Silva D. Erythrocyte antioxidant enzymes in patients with cataract. *Ann. Clin. Lab. Sci.*, 2006; 36:201-204.
12. Murugesan GS, Sathishkumar M, Jayabalani R, Binupriya A.R, Swaminathani K, Yuri S.E. Hepatoprotective and alterative properties of kombucha tea against carbon tetrachloride-induced toxicity. *J. Microbiol. Biotechnol.*, 2009; 19(4):397-402.
13. Burkil HM. The useful plants of net. Tropical Africa. 4th Edition Macmillan Press: 1999; 1:34-36.
14. El-kamali HH, Abdalla BM, Al-magboul AZ. Antibacterial properties of some essential oils against fine enterobacteriaceae species AL-Bututh., 2007; 11(2):11-19.
15. Edeoga HO, Okwu DE, Mbaebie BO. Phytochemical constituents of some Nigerian medicinal plants. *Afr. J. biotechnol.*, 2005; 4(7):685-688.
16. Hukkeri VI, Jaiprakash B, Lauhale MS, Karadi RV, Kuppast IJ. Hepatoprotective activity of *Ailanthus excels roxb*: leaf extract experimental liver damage on rats. *Pharmacognosy.*, 2003; 11:1-2.
17. Patrick-iwuanyanwu KC, Wegwu MO, Okiyi JK. Hepatoprotective effects of African locust bean and negro pepper in CCl₄ induced liver damage on wistar albino rats. *Int. J. Pharmacol.*, 2010; 6(5):744-749.
18. Obi FO, Usenu IA, Osayande JO. Prevention of CCl₄-induced hepatotoxicity in rat by *H. rosasinensis* anthocyanin extract administered in ethanol. *J. Toxicol.*, 1998; 131:93-98.
19. Wegwu MO, Ayalogu EO, Sule OJ. Antioxidant protective effects of *Cassia alata* in rats exposed to carbon tetrachloride. *J. Applied Sci. Environ*, 2005; 9:77-88.
20. Patrick-Iwuanyanwu KC, Wegwu MO, Ayalogu EO. Prevention of CCl₄-induced liver damage by ginger, garlic and vitamin E. *Pak. J. Biol. Sci.*, 2007; 10:617-621.
21. Lin JK, Wang CJ. Protection of crocin dyes on the acute hepatic damage induced by Afla toxin B and dimethyl nitrosamine in rats. *Carcinogenic.*, 1986; 7: 595-599.
22. Shenoy KA, Somayi SN, Bairy KL. Hepatoprotective effects of *Ginkgo biloba* against carbon tetrachloride induced hepatic injury in rats. *Ind. J. Pharmacol.*, 2001; 33: 260-266
23. Rotruck JT, Pope AL, Ganther H, Awanson AB, Haffeman DG, Hofekstra WG. Selenium: Biochemical role as a component of glutathione peroxidases. *Science*, 1979; 179:588-590.
24. Lin CC, Huang PC. Antioxidant and hepatoprotective effects of *Acatopanax senticosus*. *Phytother. Res.*, 2000; 14:489-494.
25. Sathe R, Tredger JM, Williams R. Drugs and the liver part 1: Testing liver function. *Biopharm. Drug Dispos.*, 1991; 12:251-259.
26. Thabrew MI, Joice PD, Rajatissa WA. Comparative study of efficacy of *Paetta indica* and *Osbeckia octandra* in the treatment of liver dysfunction. *Planta medica*, 1987; 53:239-241.
27. Sofowora A. The medicinal plants and traditional medicine in Africa. *J. Phytochem.*, 2001; 34(8): 223-230.
28. Prakash O, Singh GN, Singh RM, Mathur SC, Bajpai M, Yadav S. Protective effects of herbal formula against carbon tetrachloride-induced hepatotoxicity. *Int. J. Pharmacol.*, 2008; 4: 282-286.
29. Misra H, Fridovich I. The role of superoxide anion in the antioxidation of epinephrine and a sample assay for superoxide dismutase. *J. Biol. Chem.*, 1972; 247:3170-3175.
30. Hukkeri VI, Jaiprakash B, Lauhale MS, Karadi RV, Kuppast IJ. Hepatoprotective activity of *Ailanthus excels roxb*: leaf extract experimental liver damage on rats. *Pharmacognosy.*, 2003; 11:1-2.
31. Aebi H. Catalase in vitro: methods in enzymology, 1984; 105: 121-126.
32. Hunter FE, Gebicki PE, Hoffsetein JW, Scott A. Swelling and lysis of rats liver mitochondria induced by ferrous ions. *J. Biochem.*, 1963; 238:828-835.
33. Habig WH, Pabst MJ, Jakob WB. Glutathione S-transferases, the enzymatic step in mercapturic acid formation. *J. Biol. Chem.*, 1974; 249(22):7130-7139.
34. Gulteridge JMC, Wilkin C. Copper dependent hydroxyl radical damage to ascorbic acid formation of a thiobarbituric acid reactive products. *FEBS Lett*, 1980; 137:327-340.