

The Journal of Phytopharmacology

(Pharmacognosy and phytomedicine Research)

Research Article

ISSN 2230-480X

JPHYTO 2015; 4(4): 197-201

July- August

© 2015, All rights reserved

1: Laboratory of Vegetable Raw Materials Extraction and Bioconversion, Institute of Food Biotechnology and Genomics of the National Academy of Sciences of Ukraine, Ukraine, Kyiv, 04123, 2a Osipovskogo st.

2: Laboratory of Morphology and Cytology, D.F. Chebotarev State Institute of Gerontology National Academy of Medicinal Sciences of Ukraine, Ukraine, Kyiv, 04114, 67 Vyshhorodska st.

3: Laboratory of Pathophysiology and Immunology, D.F. Chebotarev State Institute of Gerontology National Academy of Medicinal Sciences of Ukraine, Ukraine, Kyiv, 04114, 67 Vyshhorodska st.

Correspondence:

Victor Yu. Barshteyn

Laboratory of Vegetable Raw Materials Extraction and Bioconversion, Institute of Food Biotechnology and Genomics of the National Academy of Sciences of Ukraine, Ukraine, Kyiv, 04123, 2a Osipovskogo st.

Effects of *Ganoderma lucidum* (Curtis) P. Karst and *Crinipellis schevczenkovi* Buchalo aqueous extracts on skin wound healing

Tetiana A. Krupodorova¹, Pavlo P. Klymenko², Victor Yu. Barshteyn^{1*}, Yuri I. Leonov³, Dmytro W. Shytikov³, Tetiana N. Orlova³

ABSTRACT

The aqueous extracts of *Ganoderma lucidum* 1900 (Curtis) P. Karst and *Crinipellis schevczenkovi* 31 Buchalo mycelia were investigated for skin wound healing activity in vivo using the excision wound healing model. The extracts were prepared by mixing of 100 mg of powdered mycelium of both mushrooms with 1 mL of sterile distilled water for injections. White albino mice line FVB/Cg., 3 months of age (male), were used for the study. The rate of wound healing and the histology of healed wounds in mice have been studied. Visual method of wound study and histological investigation of skin tissue showed the presence of wound healing potential of *G. lucidum* and *C. schevczenkovi* mycelia. The wound healing process was expressed more active on 3th day in case of topical application of *C. schevczenkovi* mycelium extract, but on 5th day the wound healing effects of both mushroom extracts were almost at the same level and statistically better than results in the control group. Wounds treated with mycelial extracts were covered completely on the 6th day compared with 8th day in control group. Wound healing ability of *C. schevczenkovi* observed in present investigations for the first time.

Keywords: Skin wound healing, *Ganoderma lucidum*, *Crinipellis schevczenkovi*, Mycelium, Aqueous extract.

INTRODUCTION

Searching and investigation of effective substances that promote wound healing are one of the developing trends in modern biomedical sciences. The attention of the researchers is attracted primarily to the great potential of Phytomedicine because of the ability of plants for wounds healing through natural repair mechanisms. Today, more than 70% of wound healing pharma products are based on plants, 20% – on the mineral compounds and remaining containing of animal products as their base material [1]. In this regard, cannot but cause the interest higher fungi (extracts from fruit bodies, spores, mycelia or isolated compounds), which have a wide range of therapeutic properties. The development of effective and simple technologies of higher fungi cultivation, a range of characteristic features of fungi, namely fast growth, biomass and metabolites production, advances in the study of metabolic processes in fungi, introduction of new fungi species to *in vitro* culture and creation of *in vitro* fungi culture collections had widened the scope of their applications. Some medicinal mushroom species belonging to Basidiomycetes are found useful in different wounds treating. Some experiments have shown that lectin from fruit bodies of *Agaricus bisporus* (ABL) possesses key features required of an agent that might control scarring processes and suggest that ABL might be especially useful where subtle modification of healing after glaucoma surgery is needed [2]. ABL is also a perspective agent in the prevention and treatment of proliferative vitreoretinopathy (anomalous wound healing response) [3]. The polysaccharides fraction as well as ethanol extract of *Ganoderma lucidum* fruiting bodies [4, 5] and aqueous extract of *Hericium erinaceus* basidiocarp [6, 7] appeared the antiulcer effect in rats. Dry ethanol mycelial extract and cultural filtrate of *Lentinus edodes* shows antiprotozoal activity and mitogenic effect and may be used for creation of biopreparations in wound healing and other regenerative processes [8]. *L. edodes* polysaccharide (LEP) administration significantly raised activities of serum antioxidant enzymes and decreased levels of serum, mucosal interleukin-2 (IL-2) and tumor necrosis factor alpha (TNF- α) in rats with oral ulceration. So, LEP may play a part in ameliorating oral ulceration [9]. Perspective results has been demonstrated for Protein (Ling Zhi-8) from *G. lucidum* which can induced acceleration of wound healing in rat liver tissues after monopolar electrosurgery [10]. Application of *Agaricus blazei* polysaccharides has been found useful in burn wound healing – increased the percentage of wound contraction through rapid epithelization and collagenization [11]. A significant number of investigations devoted to the higher mushrooms influence on skin wound (of different origin) healing. Polysaccharides (fruiting bodies aqueous extracts) obtained from *Phellinus gilvus* [12] and *G. lucidum* promote

dermal wound healing in streptozotocin-induced diabetic animals [13, 14]. Wounds dressed with *H. erinaceus* fruiting bodies aqueous extract significantly enhanced the acceleration of wound healing enclosure in rats [15]. Wound healing promoting effect of polysaccharides purified from *Tremella fuciformis* and *Auriporia auricular* fruiting bodies aqueous extracts has been demonstrated on *ex-vivo* porcine skin wound healing model [16]. *A. bisporus* extract have beneficial effects on skin in regeneration due to increasing proliferative epidermal cells as well as suppressing cell death and inflammatory reaction [17]. Sacchachitin membrane, isolated from the residual fruiting body of *Ganoderma tsugae*, has been demonstrated to promote skin wound healing [18, 19]. Topical gel preparations of *Ganoderma praelongum* and *Glycyrrhiza glabra* aqueous extracts combination significantly has been increased wound contraction in excision wound and shortened the period of epithelialization nearly by two days [20]. The aqueous lyophilized extract rich in total polyphenol and flavonoid obtained from carpophores of *G. lucidum* has been reported to possess significant wound-healing activity: an increase in wound contraction, collagen accumulation (hydroxyproline), hexosamine, and total protein contents [21]. It should be emphasized the study where topical application of fungal preparation is not used to the wound, but oral administration of β -glucan purified enzymatically from *Sparassis crispa* increased migration of macrophages and fibroblasts, collagen regeneration, and epithelialization under hyperglycemic conditions [22, 23].

However, the effects of mushrooms on wound healing have been scientifically evaluated occasionally and have not been completely identified. Thus, the study of the effect of mushrooms on skin wound healing is important and actual. Moreover, the results depend on the type of fungus, its strain, the culture medium for its cultivation, the source of preparation (fruit bodies, spores, mycelia), method of its production (the medium for suspending, the extractant), and the method of its application (even oral).

The aim of the current work was the investigation *in vivo* the wound healing effect of the aqueous extracts of *Ganoderma lucidum* 1900 (Curtis) P. Karst. and *Crinipellis schevczenkovi* 31 Bukhalo mycelia, cultivated on the natural substrate (amaranth flour after CO₂ extraction).

MATERIALS AND METHODS

Fungi species and Growth Conditions

The fungi species *Ganoderma lucidum* 1900 (Cutris) P. Karst and *Crinipellis schevczenkovi* 31 Buchalo were kindly supplied by the Culture Collection of Mushrooms (IBK) of the M.G. Kholodny Institute of Botany of the National Academy of Sciences of Ukraine [24]. Mycelial cultures were initially grown in Petri dishes (90 mm diameter) on culture medium with pH 6.0, composed of (g/L): 20.0 glucose, 3.0 yeast extract, 2.0 peptone, 1.0 K₂HPO₄, 1.0 KH₂PO₄, and 0.25 MgSO₄·7H₂O. The liquid culture medium (substrate – 60 g amaranth flour in 1 L distilled water) was sterilized by autoclaving for 20 min at 121 °C. Flasks (250 mL) with 50 mL liquid medium were inoculated with three mycelial plugs of 8 mm diameter cut from the Petri dishes using a sterile borer at the stage of actively growing mycelia. Mycelia were grown as static cultures in flasks for 14 days at 26 ± 2 °C. The mycelium was separated from the medium by filtration through Whatman's filter paper № 4 and washed with distilled water, dried to constant weight at 50±2 °C and ground to power consistent using a blade grinder.

Extraction

The aqueous extract for wound healing assay was prepared by mixing of 100 mg of powdered mycelium of both mushrooms with 1 mL of sterile distilled water for injections and shaking at 60 °C for 30 minutes. Then it was centrifuged at 10000 rpm for 10 minutes. The extracts were then stored in a refrigerator at 4 °C.

Animals

Twenty five white albino mice line FVB/Cg., 3 months of age (male), were used for the study. They were maintained in air-conditioned animal house and fed on standard mouse food and water *ad libitum*.

Evaluation of wound healing

The animals were divided into three groups, with three animals per group. Group I and II were the test groups, while group III was control.

Group I: test animals were treated with 20 μ L aqueous extract of *G. lucidum* mycelium topically once daily for 6 days.

Group II: test animals were treated with 20 μ L aqueous extract of *C. schevczenkovi* mycelium topically once daily for 6 days.

Group III: the negative control was treated with sterile distilled water once daily for 8 days.

Each mice was anaesthetized with chloroform and the hair on the skin of the back was clipped. Following disinfection of the clipped area with 2% detox® solution, a full thickness circular skin incision of about 5 mm in diameter was made and carefully dissected out.

The research has been reviewed and approved by the appropriate ethics review committee.

Histological evaluation of healed wounds

Specimens of skin from healed wounds from each mouse were taken on 3th and 5th days post-surgery and fixed in 10% buffered formalin solution for further histopathological studies. Sections of the healed skin were made at a thickness of 5 μ m and, stained with hematoxylin and eosin (H & E), and assessed for histopathological changes. Determinations the length of the open wound was applied by morphometric program "Image J". The microscopic slides were photographed.

Statistical analysis

All experiments were confirmed in three independent replicates. The data were analyzed by Excel statistical functions using Microsoft Office XP software the Statistical Package for Social Sciences, Program 11.5 Version (SPSS, Inc., 2002). Values are presented as means \pm standard error of the mean (SEM). Differences at $P \leq 0.05$ were considered to be significant.

RESULTS AND DISCUSSION

The wound healing effect of aqueous extract of *G. lucidum* and *C. schevczenkovi* mycelia has been evaluated *in vivo* using the excision wound healing model. The results of present study have shown that investigated mushrooms have different potential of therapeutic activity (Fig. 1). The wound healing process was expressed more active on 3th day in case of application of *C. schevczenkovi* mycelium extract, but on 5th day the wound healing effects of both mushroom extracts were almost at the same level and statistically better then results in the control group.

The applying of the extracts from both species mycelia has caused the inflammatory process (Fig. 2 A, B). Besides, in this phase of wound healing *G. lucidum* mycelium extract application led to the increase of the wound. These findings were further confirmed at cellular level by histological studies: accumulation of neutrophils and lymphocytes (Fig. 2 C). Surfaces of wound and the growing a thin layer of epithelium were covered on the 3th day with large amount of containing lymphocytes exudate, forming an eschar (Fig. 2 D). Though healing occurs, granulation tissue was friable and edematous. Regenerative cushion on the edges of the wounds was not expressed; however, the density of granulation tissue at the edges of wounds was

increased. Under granulation tissue was found a large amount of adipose tissue (Fig. 2 E, F). Wound tissues treated with mycelial extracts showed on the 5th day the formation on the surface of the granulation tissue of a thin layer of stratified squamous keratinizing

epithelium (Fig. 2 G, H). Wounds treated with mycelial extracts were covered completely on the 6th day (Fig. 2 I, J) compared with 8th day in control group.

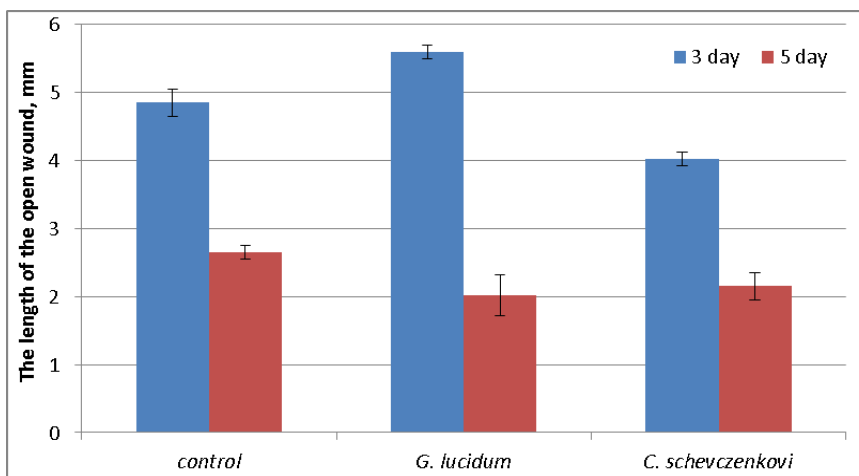


Fig. 1: The length of the open wound after exposure to aqueous extracts of mushroom mycelia.

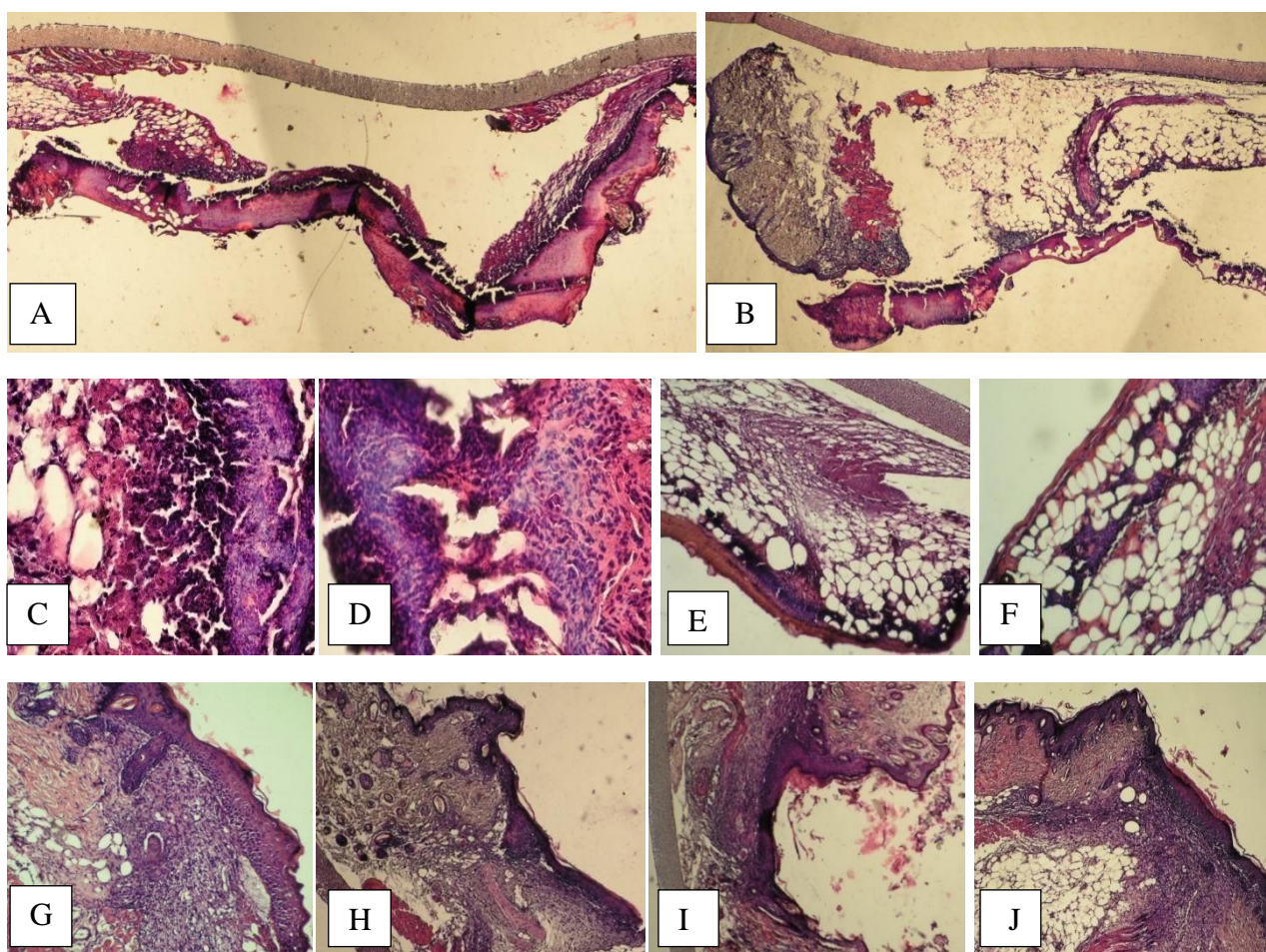


Fig. 2: Effect of mycelia aqueous extracts on histological evaluation: inflammatory process by applying of *G. lucidum* (A) and *C. schevczenkovi* (B); accumulation of neutrophils and lymphocytes (D) and eschar, exudate containing lymphocytes (E) in case of *G. lucidum* application; large amount of adipose tissue by using of *G. lucidum* (E) and *C. schevczenkovi* (F); the granulation tissue of a thin layer of stratified squamous keratinizing epithelium by treating of *G. lucidum* (G) and *C. schevczenkovi* (H); covered wound after *G. lucidum* (I) and *C. schevczenkovi* (J) extracts application. Scale bar: A, B 40µm; C, D, G 200 µm; E, F H, I, J 100 µm.

G. lucidum as one of the most known medicinal mushrooms with immense potential for therapeutic applications and *Ganoderma* spp. species causes the continuing interest of researchers, including the study of the wound healing process [4, 5, 10, 13, 14, 18, 20, 21]. Wound healing preparations, created mainly on the basis of the fruiting bodies of fungi, have a healing effect, as well as medication in our study that is based on mycelium. The presence of acute local inflammatory allergic effect of the *G. lucidum* mycelium aqueous extract in our investigation has been found in contrast to the report of Gupta *et al.* [21] who studied efficacy of skin wound healing with aqueous extract from fruit body of this fungi but in agreement with the findings of Hung *et al.* [18] in case of application the residues of fruiting body of *G. tsugae*. The effect of promoting skin wound healing has been established also for other species from genus *Ganoderma* – *G. praelongum* [20]. The second object of our study *C. schevczenkovi* is relatively poorly studied [25, 26]. Wound healing ability of *C. schevczenkovi* observed in our investigations for the first time.

We did not determine the composition of the extracts in our study. The use of water as an extraction allows us to suggest that polysaccharides constitute the bulk of the extracts which wound healing effect was studied. In the same time, the isolation and identification the active metabolites contribute a better understanding of the wound healing activity. Basidiomycetes have been found to exhibit wound healing properties due to the presence of polysaccharides [9, 11-14, 16, 22], lectin [2], protein [10]. It directly depends on extractant used for fungal preparation production. Some studies were showed the wound healing efficacy using aqueous [6, 7, 15, 21] or ethanol extracts [4, 5], or combined product with the addition of medicinal plant [20]. Substances isolated from fungi have a bactericidal effect, turn on the mechanisms of immune response and show regenerative properties.

CONCLUSION

The current study revealed that topical application of *G. lucidum* and *C. schevczenkovi* mycelia aqueous extracts possesses wound healing activity. Wound healing ability of *C. schevczenkovi* observed in present investigations for the first time and open up the new avenues for the application of *C. schevczenkovi* mycelium in the therapeutic field.

Further research is a need to isolate, identify and characterize the specific active compounds in these mushrooms responsible for wound healing activity, to understand the complete mechanism in wound repair processes.

Conflict of Interests

The authors declare that there is no conflict of interests regarding the publication of this paper.

REFERENCES

1. Kumarasamyraja D., Jeganathan N.S., Manavalan R. A Review on medicinal plants with potential wound healing activity. *Int. J. Pharma Sci.* 2012; 2(4):105–111.
2. Batterbury M., Tebbs C.A., Rhodes J.M., Grierson I. *Agaricus bisporus* (edible mushroom lectin) inhibit ocular fibroblast proliferation and collagen lattice contraction. *Exp. Eye. Res.* 2002; 74:361–370.
3. Kent D., Sheridan C.M., Tomkinson H.A., White S.J., Hiscott P., Yu L., Grierson I. Edible mushroom (*Agaricus bisporus*) lectin inhibits human retinal pigment epithelial cell proliferation. *Wound. Repair. Regen.* 2003; 11(14):285–291.
4. Gao Y., Tang W., Gao H., Chan E., Lan J., Zhou S. *Ganoderma lucidum* polysaccharide fractions accelerate healing of acetic acid induced ulcers in rats. *J. Med. Food.* 2004; 7(4):417–421.
5. Rony K.A., Mathew J., Neenu P.P., Janardhanan K.K. *Ganoderma lucidum* (Fr.) P. Karst. occurring in South India attenuates gastric ulcerations in rats. *Indian J. Nat. Prod. Res.* 2011; 2(1):19–27.
6. Abdulla M.A., Wong K.-H., Mohd A.H. Effect of culinary-medicinal Lion's mane mushroom, *Hericium erinaceus* (Bull.: Fr.) Pers.

- (Aphyllphoromycetidae), on ethanol-induced gastric ulcers in rats. *Int. J. Med. Mush.* 2008; 10(4):325–330.
7. Wong J.-Y., Abdulla M.A., Raman J., Phan C.-W., Kuppusamy U.R., Golbabapour S., Sabaratnam V. Gastroprotective effects of Lion's mane mushroom *Hericium erinaceus* (Bull.:Fr.) Pers. (Aphyllphoromycetidae) extract against ethanol-induced ulcer in rats. *Evid. Based Comp. Alternat. Med.* 2013. (doi.org/10.1155/2013/492976).
8. Badalyan S.M. Antiprotozoal activity and mitogenic effect of mycelium of culinary-medicinal Shiitake mushroom *Lentinus edodes* (Berk.) Singer (Agaricomycetidae). *Int. J. Med. Mush.* 2004; 6:131–138.
9. Yu Z.H., Yin L.H., Yang Q., Liu Y. Effect of *Lentinus edodes* polysaccharide on oxidative stress, immunity activity and oral ulceration of rats stimulated by phenol. *Carbohydr. Polym.* 2009; 75:115–118.
10. Lin H.-J., Chang Y.-S., Lin L.-H., Haung C.-F., Wu C.-Y., Ou K.-L. An immunomodulatory protein (Ling Zhi-8) from a *Ganoderma lucidum* induced acceleration of wound healing in rat liver tissues after monopolar electrosurgery. *Evid. Based Comp. Alternat. Med.* 2014. (doi.org/10.1155/2014/916531).
11. Sui Z.F., Yang R.Y., Liu B., Gua T.M., Zhao Z.L., Shi D.F., Chang D.Q. Chemical analysis of *Agaricus blazei* polysaccharides and effect of the polysaccharides on IL-1 mRNA expression in skin of burn wound-treated rats. *Int. J. Biol. Macromolecules.* 2010; 47:155–157.
12. Bae J.S., Jang K.H., Jin H.K. Polysaccharides isolated from *Phellinus gilvus* enhances dermal wound healing in streptozotocin-induced diabetic rats. *J. Vet. Sci.* 2005; 6(2):161–164.
13. Tie L., Yang H.-Q., An Y., Liu S.-Q., Han J., Xu Y., Hu M., Li W.-D., Chen A. F., Lin Z.-B., Li X.-J. *Ganoderma lucidum* polysaccharide accelerates refractory wound healing by inhibition of mitochondrial oxidative stress in type I diabetes. *Cell. Physiol. Biochem.* 2012; 29:583–594.
14. Cheng P.-G., Phan Ch.-W., Sabaratnam V., Abdullah N., Abdulla M.A., Kuppusamy U.R. Polysaccharides-rich extract of *Ganoderma lucidum* (M.A. Curtis: Fr.) P. Karst. accelerates wound healing in streptozotocin-induced diabetic rats. *Evid. Based Comp. Alternat. Med.* 2013. (doi.org/10.1155/2013/671252).
15. Abdulla M.A., Fard A.A., Sabaratnam V., Wong K.-H., Kuppusamy U.R., Abdullah N., Ismail S. Potential activity of aqueous extract of culinary-medicinal Lion's mane mushroom, *Hericium erinaceus* (Bull.: Fr.) Pers. (Aphyllphoromycetidae) in accelerating wound healing in rats. *Int. J. Med. Mush.* 2011; 1:33–39.
16. Khamlue R., Naksupan N., Ounaroan A., Nuttawust S. Skin would healing effect of polysaccharides extracts from *Tremella fuciformis* and *Auriporia auricular* on the *ex-vivo* porcine skin would healing model. In: 4th Inter. conf. on Chemical, Biological and Environmental Engineering. IACSIT Press, Singapore. 2012; 43(20):93–98.
17. Lam W.P., Wang C.M., Tsui T.Y., Wai M.S., Tang H.C., Wong Y.W., Lam L.H., Hui L.K., Yew D.T. Extract of white button mushroom affects skin healing and angiogenesis. *Microsc. Res. Tech.* 2012; 74(10):1334–1340.
18. Hung W.S., Fang C.L., Su C.H., Lai W.F., Chang Y.C., Tsai Y.H. Cytotoxicity and immunogenicity of SACCHACHITIN and its mechanism of action on skin wound healing. *J. Biomed. Mater. Res.* 2001; 56:93–100.
19. Hung W.S., Lai W.F., Leu B., Su C.H., Fang C.L., Tsai Y.H. Effect of SACCHACHITIN on keratinocyte proliferation and the expressions of type I collagen and tissue-transglutaminase during skin wound healing. *J. Biomed. Mater. Res.* 2004; 70:122–129.
20. Ameri A., Rajive B.B., Vaidya J.G., Apte K., Deokule S.S. Anti-Staphylococcal and wound healing activities of *Ganoderma praelongum* and *Glycyrrhiza glabra* formulation in mice. *Int. J. Appl. Res. Nat. Prods.* 2013; 6 (1):27–31.
21. Gupta A., Kirar V., Keshri G.K., Gola S., Yadav A., Negi P.S., Misra K. Wound healing activity of an aqueous extract of the Lingzhi or Reishi medicinal mushroom *Ganoderma lucidum* (higher Basidiomycetes). *Int. J. Med. Mush.* 2014; 16(4):345–54.
22. Kwon A.H., Qiu Z., Hashimoto M., Yamamoto K., Kimura T. Effects of medicinal mushroom (*Sparassis crispa*) on wound healing in streptozotocin-induced diabetic rats. *The Am. J. Surg.* 2009; 197(4):503–509.
23. Yamamoto K., Kimura T. Orally and topically administered *Sparassis crispa* (Hanabiratake) improved healing of skin wounds in mice with Streptozotocin-induced diabetes. *Biosci. Biotechnol. Biochem.* 2013; 77(6):1303–1305.
24. Buchalo A.S., Mitropolskay N.Yu., Mukchaylova O.B. Culture collections of mushrooms IBK. Inc.: Kyiv, Altpress, 2011. (In Ukrainian).
25. Smirnov D.A., Babitskaya V.G., Kapich A.N., Gladkiy A.L., Sherba V.V. Effect of polysaccharides of submerged cultures of *Ganoderma lucidum*, *Lentinus edodes* and *Crinipellis schevczenkovi* on the phagocytic activity of neutrophils. *Biotech.* 2007; 1:47–51. (in Russian).

26. Krupodorova T., Ivanova T., Barsteyn V. Screening of extracellular enzymatic activity of macrofungi. *J. Microbiol. Biotech. Food Sci.* 2014; 3 (4):315–318.

HOW TO CITE THIS ARTICLE

Krupodorova T A, Klymenko P P, Barshteyn V Y, Leonov Y I, Shytikov D W, Orlova T N. Effects of *Ganoderma lucidum* (Curtis) P. Karst and *Crinipellis schevczenkovi* Buchalo aqueous extracts on skin wound healing. *The Journal of Phytopharmacology* 2015;4(4):197-201.