

The Journal of Phytopharmacology

(Pharmacognosy and phytomedicine Research)

Research Article

ISSN 2320-480X

JPHYTO 2017; 6(1): 27-33

Received: 18-02-2017

Accepted: 05-03-2017

© 2017, All rights reserved

Godfrey Mutuma Gitonga

Department of Biochemistry and Biotechnology, Kenyatta University, Nairobi City, Kenya

Joseph Ngeranwa

Professor, Department of Biochemistry and Biotechnology, Kenyatta University, Nairobi City, Kenya

Alex King'ori Machochi

Professor, Department of Chemistry, Kenyatta University, Nairobi City, Kenya

Daniel Gaichu Muthee

Department of Biochemistry and Biotechnology, Kenyatta University, Nairobi City, Kenya

Rodgers Kimutai

Department of Biochemistry and Biotechnology, Kenyatta University, Nairobi City, Kenya

Ann Wanjiru Gitonga

Department of Zoological Sciences, Kenyatta University, Nairobi City, Kenya

Nephrotoxicity effects of Khat (*Catha edulis*) on mice when administered orally

Godfrey Mutuma Gitonga*, Joseph Ngeranwa, Alex King'ori Machochi, Daniel Gaichu Muthee, Rodgers Kimutai, Ann Wanjiru Gitonga

ABSTRACT

Renal problems are currently on increase worldwide. Some factors suspected to be the cause of the renal problems are drug abuse. Hence, this study investigated possible renal toxicity effect of Khat in male albino mice. Khat alkaloids were extracted from fresh Khat shoots and leaves. The Khat extract were administered orally through intubation. Accordingly, forty- five albino mice (20 – 25g) were distributed randomly into nine groups (n = 5). Negative controls (NCs) received purely distilled water. Positive controls (PCs) received indomethacin at a dosage of 2mg/Kg/day as a twice dose per day. Test groups received Khat extract administered in combination of 2ml tea, 2ml water, 2ml milk, 2ml coffee, 2ml coke, 2g patico sweet and 2g groundnut. To each test group Khat extract was administered at a dosage of 2000mg/Kg/day for four weeks. Blood samples were collected from all animals for biochemical analysis after four weeks which included the renal function tests such as serum creatinine and blood urea nitrogen levels. The histological and cytological studies were done using H&E staining technique. There was an increased level of renal biochemical markers in all albino mice serum exposed to Khat extract. There was a significant different between levels of renal biochemical enzymes biomarkers at $p < 0.05$. There were signs of adverse effects of Khat on kidney of mice.

Keywords: Cathine, Cathinone, Nephrotoxicity.

INTRODUCTION

Khat scientifically known as *Catha edulis* (Vahl) is an evergreen flowering or shrub belonging to the family Celastraceae.^[1,2] More than 10 million people worldwide are using Khat for euphorizing and psychostimulating effect.^[3,4] Khat is cultivated as a small tree (Figure 1). It reaches heights of 1.5 meters to 20 meters depending on the amount of rainfall and soil conditions. The tree leaves are slightly sweet with astringent taste and have aromatic odour. The taste of the Khat leaves varies from one kind to another and depends on the tannic content. The young leaves are slightly sweet.^[5] Khat plant do not bear fruits hence it is seedless. Khat plant is able to grow in different climatic region and variety of soils. The plant is pruned to attain a desired shape, for easy harvesting and to encourage growth of shoots^[6] (Figure 2). In the past, Khat consumption was localized within the region where it is grown. Recently with improved means of transport, Khat consumption is widely distributed all over the world. Khat is mainly harvested in the morning hours and immediately transported to the market in terms arranged in form of bundles (Figure 3).



Figure 1: Young Khat plant



Figure 2: Pruned Khat plant before pruning



Figure 3: A bundle of Khat stalks ready for marketing

Nephrotoxicity

The kidneys are bean shaped organs located on both sides of the vertebral column. They received blood

Correspondence:

Godfrey Mutuma Gitonga

Department of Biochemistry and Biotechnology, Kenyatta University, Nairobi City, Kenya

Email: [mutumagitonga1\[at\]gmail.com](mailto:mutumagitonga1[at]gmail.com)

through renal artery. Nephrons are the functional unit of the kidney in which urine is formed by filtering the blood. They are involved in the removal of waste products and toxic substances in the body. Small ions and water molecules as well as other small molecules are reabsorbed back to the peritubular capillaries by reabsorption. Waste molecules and ions remain in the urine and are eliminated through the urine. Drugs are responsible for the causes of acute kidney injury.^[7]

The Nephrotoxicity caused by the poisonous effect of chemical substances and drugs on the kidneys. The substances displaying Nephrotoxicity are referred to as nephrotoxins. The nephrotoxic effect of a substance is more pronounced in patients already suffering from renal impairment. Chronic use of drugs can also lead to nephrotoxicity, in cases of nephrotoxicity the kidneys fail to remove excess urine as well as waste. In cases of kidney failure, there is accumulation of toxic metabolites in the body leading to complications such as edema, ascites and hepatomegaly.^[8] The kidney damage leads to a fall in creatinine clearance causing elevation of creatinine concentration in the blood.^[9] Kidney damage due to drug toxicity can occur due to apoptosis and cellular death.^[10] Chronic renal damage is characterized by arteriopathy and tubulointerstitial fibrosis effects which are irreversible and leads to end stage renal disease.^[11] Some substances also have diuretic effects hence they are associated with disruption of epithelial sodium channels function in the collecting tubules. They inhibit the ability of aldosterone to facilitate apical membrane sodium channel expression which results in sodium loss. This is due to impaired stimulatory effects of ADH on adenylate cyclase. Decreased levels of cAMP leads to nephrogenic diabetes insipidus.^[12]

Khat abuse is associated with decrease in flow of urine in healthy men.^[13,14] This is due to probably mediation of α_1 -adrennergic receptors stimulation by cathinone. It can be demonstrated by complete blockage by indoramin which is a selective antagonist of α_1 -adrennergic receptors.^[15] Health effects of Khat are a worldwide concern.^[16] Some adverse effects on the peripheral systems focus on the cardiovascular systems, psychological and neuropharmacological effects.^[17-20] Others are oral diseases such as periodontitis, oral leukoplakia and oral cancer.^[21]

MATERIALS AND METHODS

The experiment involved forty five (N = 45) male albino mice which were distributed randomly into nine groups each with five (n = 5) animals. The animals were bred at the zoological sciences department and experiment was carried out in Biochemistry laboratories, Kenyatta University, Kenya. The study was approved by Kenyatta University animal care and use committee (KU – ACUC) number 14402/09/2014. The Khat plant material involved in the study was collected from a controlled farm to ensure that they were pesticides or any other chemicals free. Alkaloid extraction protocol was employed in the study.^[22] The fresh Khat sample including the soft stem barks, shoots and leaves were collected in the summer. Plant samples were weighed and then washed thoroughly using distilled water before chopping and grinding them into fine paste using mortar and pestle. Approximately, 200 g of the paste was placed in thirty 1000mL Erlenmeyer flask before suspending in 300mL of 0.1N hydrochloric acid (0.1N, HCl). To prevent extract destruction by sunlight, all conical flasks were covered with aluminum foil. Sonication of mixture was carried out for approximately 30 minutes, then shaken for 10 minutes at 120 shakes per minutes using a shaker before filtering using a suction pump. The residue plant material remain in the conical

flask was washed using 140ml of 0.1 N HCl. The filtrate was extracted twice with 100mL of dimethyl ether. The diethyl ether fraction was separated using 1000mL separatory funnel. The aqueous acidic fraction was extracted twice with chloroform and then the acidified fraction was separated using 1000mL separatory funnel. Saturated sodium hydroxide (10%, NaOH) was added drop by drop to acidic aqueous fraction until a pH of 10 was attained.

Diethyl ether (100mL) was used to extract the basic mixture twice before separation using 1000mL separatory funnel. Precipitates were formed by addition of Oxalic acid (1%) in diethyl ether drop wise. After standing for 20 hours at 6°C the precipitate were filtered using No. 1 Whatmann filter paper and then dried at a room temperature for approximately 48 hours. The concentrate of the sample extract was prepared by dissolving 1g of Khat extract in 5mL DMSO. The concentrate was subdivided into aliquots (200 μ L) which were stored in freezer. The presence of active compounds in Khat was verified using TLC plates.

The experimental animals were clinically monitored by veterinarian. Metal wire meshed cages measuring 30 × 30 × 30cm raised at approximately 0.75M above the ground were used to house the experimental albino mice. The cages were labelled clearly from number one to nine. Wood shavings were used in the cages to serve as the beddings. The negative control group of experimental albino mice was administered with rodent pellet and clean drinking water only. The positive control group was administered with 2mg/Kg/day as a twice dose per day (group 2). The 7 test groups of mice were administered with 2000 mg/Kg/day of Khat extract and either 2mL water (group 3), 2 mL coffee (group 4), 2 mL milk (group 5), 2 mL tea (group 6), 2 g patico sweet (group 7), 2 g of groundnut (group 8) and 2 mL coke (group 9) for 30 days. The blood samples were collected for renal function tests of all mice in all groups on the 31st day. After collection of the blood sample for biochemical tests, the experimental albino mice were sacrificed to obtain the kidneys for histocytological analysis. Haematoxylin and eosin technique was employed to carry out histocytological analysis.

The renal function tests were carried out using Cobas Integra® 400 plus automatic Chemistry Analyzer (Roche Diagnostics, Mannheim, Germany). The renal function tests carried out in the experiment were: Blood urea nitrogen (BUN) and creatinine concentration. For statistical analysis SPSS software (Version 17 SPSS inc. Chicago, Illinois) was employed. The arithmetic means and standard deviation was calculated. The p-values were examined by paired student t-tests. The results were considered significant by p-value <0.05 all end points were analyzed using 2-tailed test.

RESULTS AND DISCUSSION

Kidney weight

The mean absolute kidney weight of the positive control group was slightly higher than that of the test groups in which Khat extract was administered (Table 1). The group in which Khat extract and patico sweet was administered had highest kidney weight (0.35 \pm 0.09 g). The absolute kidney weight is well demonstrated in figure 4.

Table 1: Absolute Kidney weight in grams of male albino mice after treatment with *Catha edulis* extract for 30 days at a dosage of 2000mg/kg/day and different accompaniments as used by *Catha edulis* abusers.

Group	Treatment	AKW in grams
1	No Khat extract (-ve control)	0.25±0.04
2	Indomethacin (+ve control)	0.31±0.04
3	Extract + water	0.26±0.06
4	Extract + coffee	0.29±0.04
5	Extract + milk	0.31±0.09
6	Extract + tea	0.31±0.03
7	Extract + patico sweet	0.35±0.09
8	Extract + groundnut	0.28±0.07
9	Extract + coke	0.27±0.03

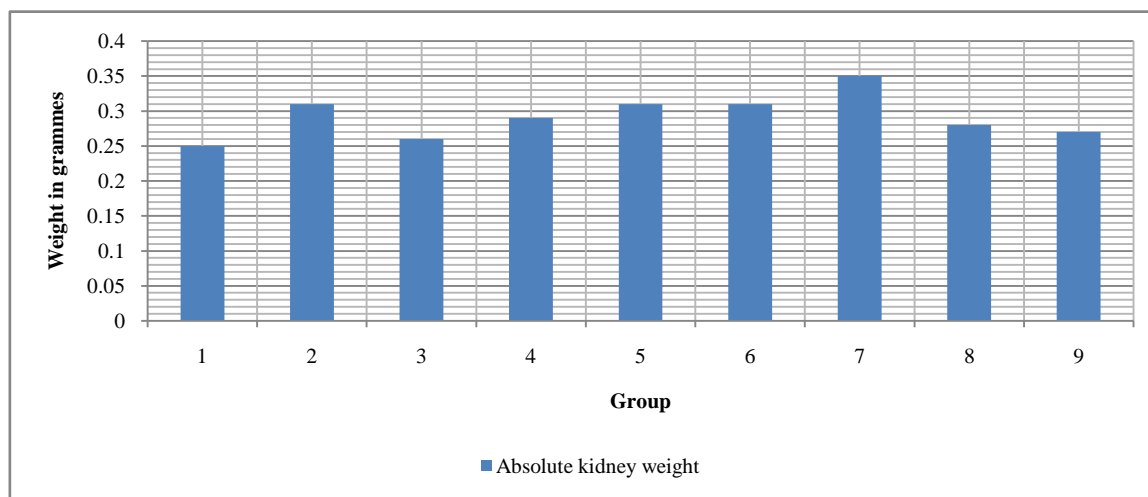


Figure 4: The mean absolute kidney weight in grams of different groups of male albino mice administered with Khat extract with different combinations of non-alcoholic substances for 30 days at a dosage of 2000mg/Kg/day

There was no significant different between the mean absolute weight of the positive control group, negative control group and the test groups which Khat extract was administered. The increase in kidney weight observed in some experimental groups can be associated with renal enlargement. Hypertrophied kidney leads to enlargement and increase in organ weight than normal.^[23] Renal enlargements is a clear feature that represents renal damage due to regeneration process.^[23] A lot of the xenobiotics which are associated with kidney damage results into enlargement of these organs and increase in their weight.^[24]

Renal biochemical tests

The blood urea nitrogen (BUN) concentration was significantly different between the negative control (no Khat extract administration) and the test groups (administered with Khat extract)

(paired t test, P < 0.05) (Table 2). There was no significant difference between the positive control (treated with indomethacin) and the test group (treated with Khat extract) in which hat extract was administered (paired t test, P < 0.05). The blood urea nitrogen (BUN) concentration for the positive control (treated with indomethacin) group was higher than that of the negative control (not treated with Khat extract) group and other tests groups which Khat extract was administered (Figure 5). The average level of the blood urea nitrogen (mMol/L) was higher in the positive control group (treated with indomethacin) (15.64 ± 1.42mMol/L as compared to negative control (not administered with khat extract) group (8.46 ± 1.29mMol/L). there was no significant difference between the positive control (treated with indomethacin) group and the group to which Khat extract was administered in combination with: milk, water, coke, tea, coffee, groundnut and patico sweets (Table 3).

Table 2: The mean serum biochemical assayed levels of blood urea nitrogen (BUN) mMol/L in male albino mice after treatment with *Catha edulis* extract for 30 days at a dosage of 2000mg/Kg/day.

Treatment	Group	BUN in mMol/L Mean±SD	P<0.05
No Khat extract (-ve control)	1	8.46±1.29	-
Indomethacin (+ve control)	2	15.64±1.42	0.000*
Extract + water	3	13.54±0.97	0.050*
Extract + coffee	4	13.82±1.00	0.060*
Extract + milk	5	13.86±2.85	0.037*
Extract + tea	6	13.16±1.64	0.008*
Extract + patico sweet	7	12.78±1.40	0.021*
Extract + groundnut	8	13.66±1.39	0.009*
Extract + coke	9	14.30±0.60	0.000*

*Significance difference as compared with normal control at p<0.05, SD = standard deviation, n =number

Table 3: Serum blood urea nitrogen (BUN) significance difference at $p < 0.05$ in different groups of male albino mice after treatment with *Catha edulis* extract for 30 days at a dosage of 2000mg/Kg/day

Treatment	NC	PC	EW	EC	EM	ET	EP	EG	Eck
NC	-	0.000*	0.050*	0.060*	0.037*	0.008*	0.021*	0.009*	0.000*
PC	0.000*	-	0.070	0.156	0.386	0.077	0.072*	0.139	0.075
EW	0.050*	0.070	-	0.609	0.832	0.685	0.326	0.789	0.267
EC	0.060*	0.156	0.609	-	0.967	0.409	0.011*	0.798	0.523
EM	0.037*	0.386	0.832	0.967	-	0.608	0.242	0.889	0.778
ET	0.008*	0.077	0.685	0.409	0.608	-	0.668	0.697	0.251
EP	0.021*	0.072	0.326	0.011*	0.242	0.668	-	0.270	0.159
EG	0.009*	0.139	0.789	0.789	0.889	0.697	0.270	-	0.450
Eck	0.000*	0.075	0.267	0.523	0.778	0.259	0.159	0.450	-

*indicates a significant difference at p value < 0.05 . BUN =Blood urea nitrogen, NC =Normal control, PC=Positive control, EW=Extract and water, EC=Extract and milk, ET=Extract and tea, EP=Extract and patico sweet, EG= Extract and groundnut, Eck=Extract and coke.

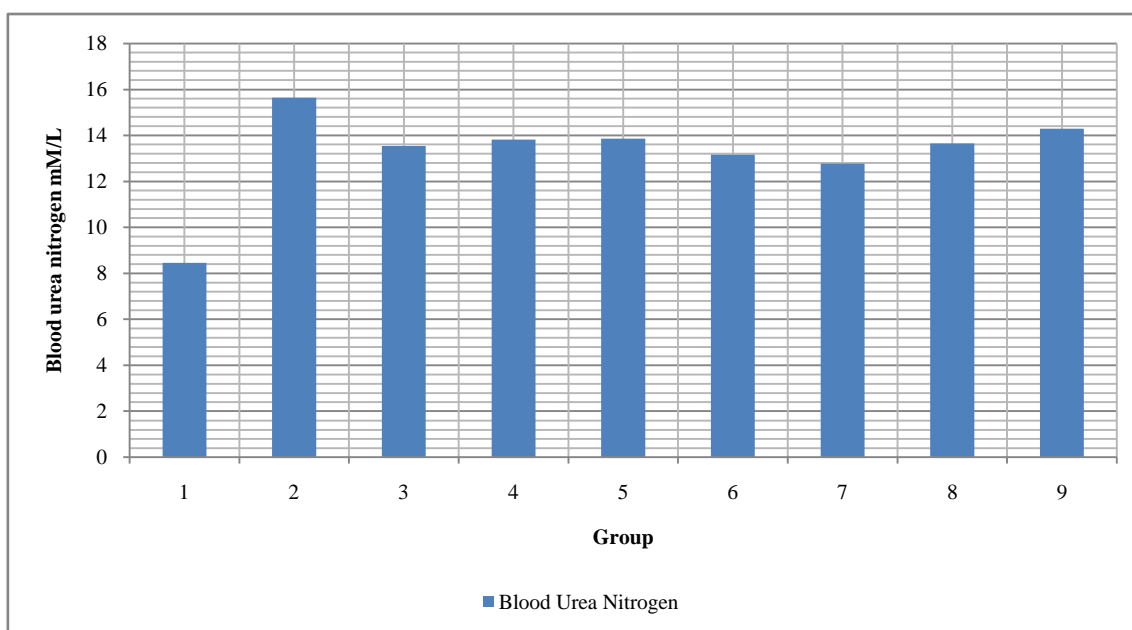


Figure 5: The mean serum biochemical assayed levels of blood urea nitrogen (BUN) mMol/L in male albino mice after treatment with *Catha edulis* extract for 30 days at a dosage of 2000mg/Kg/day

Khat extracts oral administration resulted to altered levels blood urea nitrogen (BUN) in the serum of the albino mice to which it was administered.

The blood creatinine concentration was significantly different between the negative control group and the tests groups (paired t test, $P < 0.05$) (Table 4). There was no significant different between the positive control and the test groups unto which Khat extract was administered (paired t test, $P < 0.05$). The blood creatinine concentration for the positive control group was higher than that of the negative control group and other test groups which Khat extract was administered (Figure 6). According to the study, the average level of the blood creatinine concentration ($\mu\text{M/L}$) was higher in the positive control group ($14.62 \pm 1.48 \mu\text{M/L}$) as compared to negative control group ($10.64 \pm 0.83 \mu\text{M/L}$). There was no significance difference between the levels blood creatinine concentration in the positive control (treated with indomethacin) group and the group to which Khat extract was administered with combination of milk, water, coke, tea, coffee, groundnut and patico sweets (Table 5).

Creatine phosphate, a storage compound with high energy in the muscle produces creatinine. Creatine phosphate in the muscles is spontaneously degraded to cyclic anhydride creatinine. In a normal individual the levels of serum creatinine remains fairly constant hence it's a good indicator, of assessing the functionality of the kidney. [25]

About 45% of the body's non-protein nitrogen is urea. Urea in human is the major catabolic end product. The liver synthesizes the urea after that it is excreted through the kidneys. Assessment of blood urea nitrogen is a vital parameter for assessment of renal and hepatic integrity. [25] Creatinine (Cr) and blood urea nitrogen (BUN) elevation indicates xenobiotics effects on the structure and the functions of the kidney. [24,26] The effect on the levels of creatinine and urea levels in the blood indicates impairment of kidney function or dehydration (dehydration). The physical, hematological and biochemical examinations cannot rule out the effects of khat hepato-and nephrotoxicity without carrying out histological examinations. [27-30]

Table 4: The mean serum biochemical assayed levels of blood creatinine concentration ($\mu\text{M/L}$) in male albino mice after treatment with *Catha edulis* extract for 30 days at a dosage of 2000mg/Kg/day

Treatment	Group	Creatinine ($\mu\text{M/L}$) Mean \pm SD	P<0.05
No Khat extract (-ve control)	1	10.64 \pm 0.83	-
Indomethacin (+ve control)	2	14.62 \pm 1.48	0.003*
Extract + water	3	13.58 \pm 1.19	0.024*
Extract + coffee	4	13.36 \pm 0.93	0.012*
Extract + milk	5	13.70 \pm 1.47	0.036*
Extract + tea	6	13.70 \pm 1.34	0.008*
Extract + patico sweet	7	12.34 \pm 0.90	0.016*
Extract + groundnut	8	13.48 \pm 2.19	0.011*
Extract + coke	9	13.58 \pm 2.02	0.044*

*Significance difference as compared with normal control at $p < 0.05$, SD = standard deviation, = numbe

Table 5: Serum creatinine concentration significance difference at $p < 0.05$ in different groups of male albino mice after treatment with *Catha edulis* extract for 30 days at a dosage of 2000mg/Kg/day

	NC	PC	EW	EC	EM	ET	EP	EG	Eck
NC	-	0.003*	0.024*	0.012*	0.036*	0.008*	0.016*	0.011*	0.044*
PC	0.003*	-	0.245	0.116	0.445	0.222	0.015	0.293	0.463
EW	0.024*	0.245	-	0.742	0.795	0.856	0.087	0.944	1.000
EC	0.012*	0.116	0.742	-	0.661	0.646	0.177	0.924	0.865
EM	0.036*	0.445	0.795	0.661	-	1.000	0.139	0.889	0.887
ET	0.008*	0.222	0.856	0.646	1.000	-	0.007*	0.814	0.887
EP	0.016*	0.015*	0.087	0.177	0.139	0.007*	-	0.225	0.175
EG	0.011*	0.293	0.944	0.924	0.889	0.814	0.225	-	0.939
Eck	0.044*	0.463	1.000	0.865	0.887	0.887	0.175	0.939	-

*indicates a significant difference at $p < 0.05$ NC =Normal control, PC=Positive control, EW=Extract and water, EC=Extract and milk, ET=Extract and tea, EP=Extract and patico sweet, EG= Extract and groundnut, ECK=Extract and coke

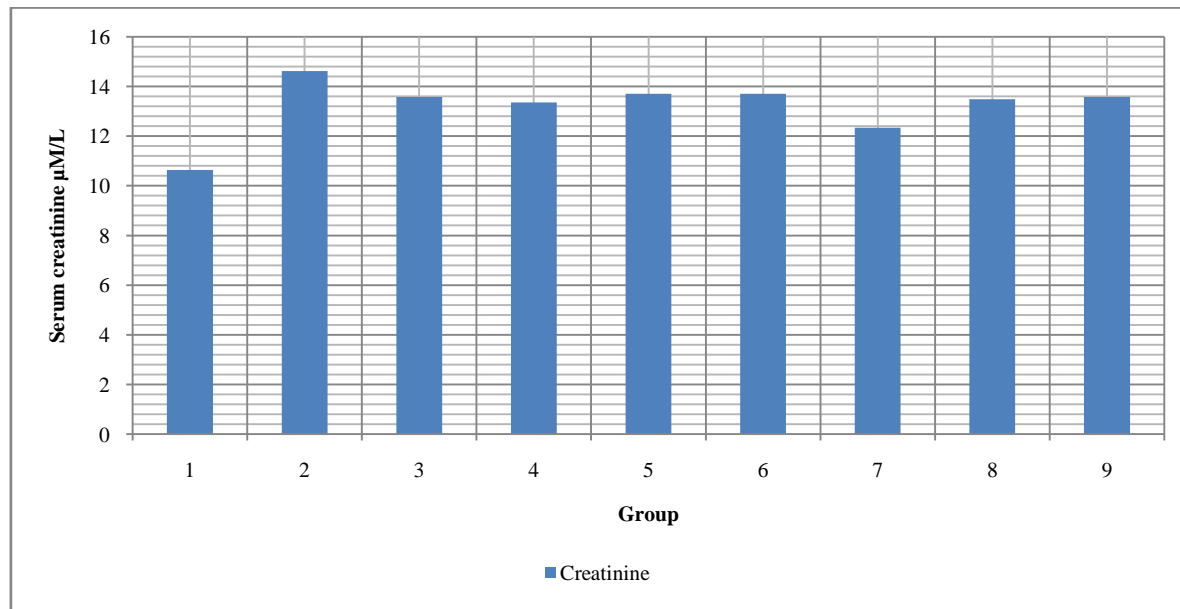


Figure 6: The mean serum biochemical assayed levels of serum creatinine concentration $\mu\text{M/L}$ in male albino mice after treatment with *Catha edulis* extract for 30 days at a dosage of 2000mg/Kg/day.

Histocytological examination

The microscopic examination of the sections of the kidney obtained from the normal group (group 1) indicated normal tubules, glomerular capillaries, Malpighian corpuscles and Bowman’s capsule (Figure 7). The kidneys of the albino mice treated with Khat extract and the positive control group indicated many areas of tubular damages

ranging from mild to severe. Some of the histopathological observations were:-signs of amorphous Malpighian corpuscles, invasive infiltrative inflammatory cells signs, hypertrophied glomerular capillaries especially at Malpighian corpuscles of kidney and atypical tubules. In some groups hyperaemia of kidney vessels were also observed (Figure 8). The frequencies of abnormalities observed are as indicated in figure 9.

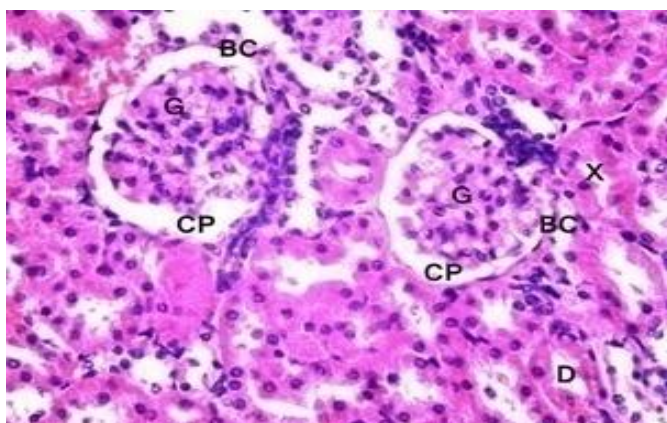


Figure 7: Light photomicrography of kidney of negative control. (G): normal glomeruli showing normal structure, (X): proximal lined with typically thick cubic epithelium, (D): distal convoluted tubules lined with relatively low simple epithelium, (CP): normal capsular space, (BC): glomerular capsule lined with flat epithelium. H&E, ×400

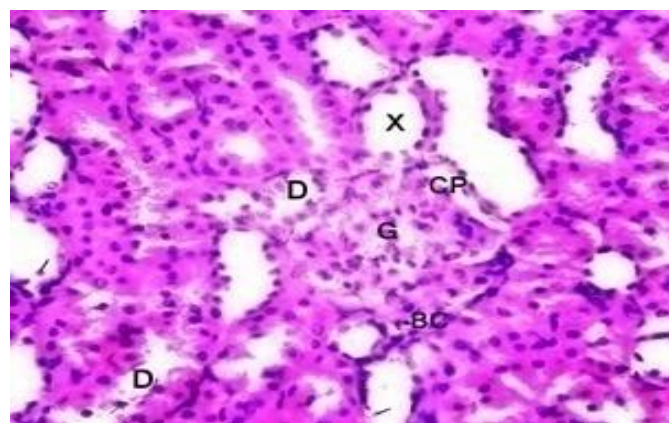


Figure 8: Moderate kidney injury photomicrography (G): enlarged vascular glomeruli, (CP): tightly filled glomerular capsular space, (BC): Bowman's capsule with flat epithelial lining, (X): proximal tubule epithelium with features of oedema, (D): distal convoluted tubule with features of oedema. (Black lines) Capillaries filled with blood cells with some tubules containing single desquamated cells. H&E, ×4000

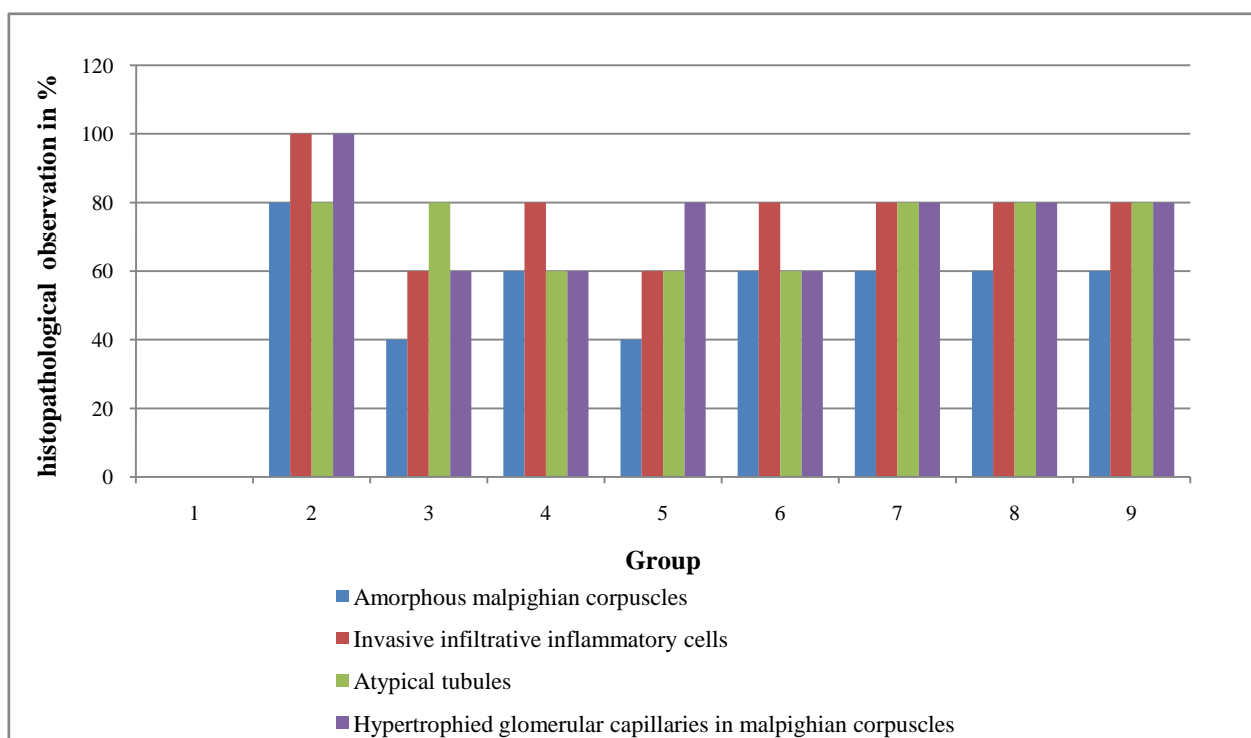


Figure 9: Histological observations kidney tissues of albino mice

Concentration of the drugs in the body affects constriction of the renal capillaries in order to decrease glomerular filtration, which minimizes the effects of the drug and protects the tubular cells.^[31] Capillaries constriction leads to glomeruli shrinkage and atrophy. This may also lead to retraction and contraction of the mesangial cells processes filaments due to angiotensin II stimulation in the cells. After 4 weeks glomerular hypertrophy is due to mesangial cells proliferation because

CONCLUSIONS

The level of kidney function tests biomarkers: creatinine and blood urea nitrogen (BUN) concentration were higher in the test groups (treated with Khat extract) as compared to the negative control (administered with rodent pellet and water only) which indicated that Khat extract had an adverse effect on the renal cells and tissues. Lack

of the secretion of more matrixes. The lesion of tubules with invasion of the inflammatory cells into the intertubular tissues is to minimize the renal tissue injury.^[32] The proximal convoluted tubules of the renal cells became edematous because of distention and retraction of microvilli and also destruction of some cells. Edematous of the renal cells is as a result of decreased rate of reabsorption of glomerular filtrate to counteract the toxicity effects of the drug.^[33] of significant difference in levels of renal function tests at $p < 0.05$ between the test groups (treated with Khat extract) indicates that different non alcoholic substances like water, coffee, groundnuts, tea, milk, coke, and patico sweet did not have any adverse effect on the kidney.

The negative control group (treated with Khat extract), kidney tissue histological observation showed normal architecture. The histological

observation in the kidney tissues like amorphous malpighian corpuscles, invasion and infiltration of inflamed cells, atypical proximal and distal tubules and the hypertrophied glomerular capillaries in malpighian corpuscles indicated adverse effect on tissues of the kidney due to administration of Khat extract.

REFERENCES

- Krinikonian A.D. Khat and U.S use; an historical perspective. *Journal of Ethnopharmacology* 1984, 12: 115-178.
- Basher T.A. The use of Khat: a stimulant with regional distribution in drug problem in the socio-cultural context. *World Health Organization, Geneva*, pp. 86-93, 1987
- Andualem, M.. The prevalence and socio-demographic characteristic of Khat chewing in Jimma town, south western Ethiopia, *Ethiopia Journal of Health* 2002;12:2.
- Bongard S., Absi M., Khalil N., Habori, M. Khat use and trait anger: Effects on affects regulation during an acute stressful challenge, *Research report university of Minnesota. European Addict Review*, 2011, 17: 285-291.
- WHO. 34th Expert Committee on Drug Dependence (ECDD). Assessment of Khat (*Catha edulis*). *World Health Organization Technical Report Series*, 2006, 916: 1-25.
- Luqman, W., Danowski, T.S. The use of Khat (*Catha edulis*) in Yemen: social and medical observations. *Annals of Internal Medicine*, 1976, 85: 246-249.
- Debroe M.E., Porter G.A., Bennett W.N., Verpooten G.A. *Clinical Nephrotoxins: Renal Injury from Drugs and Chemicals*, Dordrecht, The Netherlands, Kluwer Academic Publishers, 2003
- Porter G.A., Palmer B.F., Henrich W.L., *Clinical relevance*, in *Clinical Nephrotoxins: Renal Injury from Drugs and Chemicals*, The Netherlands, Kluwer Academic Publishers, 2003, pp 3-20
- Dowling T.C., Brigliaae, Fink J.C. Characterization of hepatic cytochromeP4503A activity in patients with end-stage renal disease. *J Clin Exp Pharmacol* 73:427-434, 2003
- Grunfeld J.P., Kleinknecht D. Droz D. *Acute interstitial nephritis*, in *Diseases of the Kidney (vol II)*, 5th ed., edited by Schrier RW, Gottschalk CW, Boston, MA, Little, Brown, 1993, pp 1331-1353
- Star R.A. Perspectives in renal medicine. *Treatment of acute renal failure. Kidney Int* 54:1817-1831, 1998
- Gambaro G. Perazella M.A. Adverse renal effects of anti-inflammatory agents: Evaluation of selective and nonselective cyclooxygenases inhibitors. *J Intern Med* 253:643-652, 2003
- Hassan G.M. Gunaid A.A. El Khally F.M.Y, Murray-Lyon I.M. The subjective effects of chewing Qat leaves in human volunteers. *Ann Saudi Med* 2002;22:34-37
- INasher A.A. Qirbi A.A. Ghafoor M.A. Catterall A. Thompson A. Ramsay J.W. Murray-Lyon I.M. Khat chewing and bladder neck dysfunction. A randomized controlled trial of alpha 1-adrenergic blockade. *Br J Urol* 1995;75: 597-598.
- Hao C.M. Yull F. Blackwell T. Dehydration activates an NF- κ B-driven, COX-2-dependent survival mechanism in renal medullary interstitial cells. *J Clin Invest* 106:973-982, 2000
- Manghi R.A. Broers B. Khan R. Benguettat D. Khazaal Y. Zullino D.F. Khat use: lifestyle or addiction? *Journal of Psychoactive Drugs*, 2009, 41: 1-10.
- Cox, G. Rampes, H. Adverse effects of Khat: A review, *Advances in Psychiatric Treatment*, 2003, 9: 456-463.
- Al-Habori, M. The potential adverse effects of habitual use *Catha edulis* (Khat). *Expert Opinion on Drug Safety*, 2005, 4: 1145-1154.
- Hassan, N.A. Gunaid, A.A. and Murray, I.M. Khat (*Catha edulis*): Health aspect of Khat chewing. *Health Journal*, 2007, 13: 706-718.
- Feyissa A.M. Kelly J.P. A review of the neuropharmacological properties of Khat, *Progress in neuro-psychopharmacology and biological psychiatry*, 2009, 32: 1147-1166.
- Swan S.K. Rudy D.W. Lasseter K.C. Effect of cyclooxygenase- 2 inhibition on renal function in elderly persons receiving a low salt diet: A randomized, controlled trial. *Ann Intern Med*, 2000, 133:1-9.
- A dugna Y. Dagne E. Phytochemical studies on Khat (*Catha edulis*). *Journal of Ethnopharmacology*, 2000, 2: 27.
- Michalopoulos, G.K. Liver regeneration, *Journal of Cellular Physiology*, 213: 286-300. 2007.
- Ashafa O.T., Yakubu M.T. Grierson D.S. Afolayan A.J. Toxicological evaluation of the aqueous extract of *Felicia muricata* leaves in Wistar rats, *African Journal of Biotechnology*, 2009, 8: 949-954.
- WHO. Guidelines on standard operating procedures for Clinical Chemistry, New Delhi. pp 21-56. 2000.
- Woodman D.D. Assessment of hepatotoxicity in Animal Clinical Chemistry. Taylor and Francis, London, UK. pp 71-86. 1996.
- Chapman, M.H., Kajihara, M. Borges, G. Severe, acute liver injury and Khat leaves, *New England Journal of Medicine*, 2010, 362: 1642-1644.
- Peevers C.G. Moorghen M.Collins P.L. Gordon F.H. Liver disease and cirrhosis because of Khat chewing in UK Somali men: a case series, *Liver International*, 2010, 30: 1242-1243.
- Coton T. Simon F. Oliver., M. Kraemer, P. Hepatotoxicity of Khat chewing, *Liver International*, 2011, 31: 434-434.
- Stuyt R.J.L. Willems. S.M. Wagtmans M.J. VanHoek, B. Chewing Khat and chronic liver disease. *Liver International*, 2011, 31: 434-436.
- Traynor T.R. Smart A. Briggs J.P. Schneimann J. Inhibition of macula densa-stimulated renin secretion by pharmacological blockade of cyclooxygenase-2. *Am J Physiol Renal Physiol* 1999, 277:706-710.
- El-Banhawy M.A. Ilham I.S. Mohamed A.S. Ramadan A.R. The toxic impacts of the anti-inflammatory drug (Indomethacin) on the mice kidney tissues. *Journal Egypt General Zoology*, 1994, 14: 177-201.
- Jackson B. Lawrence R.J. Renal papillary necrosis associated with indomethacin and phenylbutazone treated rheumatoid arthritis. *Australia Medical Journal*, 1978, 8: 165-167.

HOW TO CITE THIS ARTICLE

Gitonga GM, Ngeranwa J, Machocho AK, Muthee DG, Kimutai R, Gitonga AW. Nephrotoxicity effects of Khat (*Catha edulis*) on mice when administered orally. *J Phytopharmacol* 2017;6(1):27-33.