

The Journal of Phytopharmacology

(Pharmacognosy and phytomedicine Research)

Research Article

ISSN 2320-480X

JPHYTO 2019; 8(3): 96-103

May- June

Received: 10-04-2019

Accepted: 25-05-2019

© 2019, All rights reserved

DOI: 10.31254/phyto.2019.8303

Gounoue Kamkumo Raceline

1) Laboratory of Animal Physiology, Department of Animal Biology and Physiology, University of Yaounde 1, P.O. Box 812, Yaounde, Cameroon

2) Laboratory for Phytobiochemistry and Medicinal Plants Studies, Department of Biochemistry, Faculty of Science, University of Yaounde 1, P.O. Box 812, Yaounde, Cameroon

3) Centre for Research on Filariasis and Other Tropical Diseases, P.O.Box 5797 Yaounde, Cameroon

Noukeu Kamta Bruno Aubin

1) Laboratory of Animal Physiology, Department of Animal Biology and Physiology, University of Yaounde 1, P.O. Box 812, Yaounde, Cameroon

2) Laboratory for tuberculosis research and pharmacology, Department of Biochemistry, Faculty of Science, University of Yaounde 1, P.O. Box 812, Yaounde, Cameroon

Tsakem Nangap Marius Jaures

1) Laboratory of Animal Physiology, Department of Animal Biology and Physiology, University of Yaounde 1, P.O. Box 812, Yaounde, Cameroon

2) Laboratory for Phytobiochemistry and Medicinal Plants Studies, Department of Biochemistry, Faculty of Science, University of Yaounde 1, P.O. Box 812, Yaounde, Cameroon

Youmsi Fokouo Ducos

Laboratory for Phytobiochemistry and Medicinal Plants Studies, Department of Biochemistry, Faculty of Science, University of Yaounde 1, P.O. Box 812, Yaounde, Cameroon

Ngueguim Tsofack Florence

Laboratory of Animal Physiology, Department of Animal Biology and Physiology, University of Yaounde 1, P.O. Box 812, Yaounde, Cameroon

Dzeufiet Djomeni Paul Desire

Laboratory of Animal Physiology, Department of Animal Biology and Physiology, University of Yaounde 1, P.O. Box 812, Yaounde, Cameroon

Dimo Théophile

Laboratory of Animal Physiology, Department of Animal Biology and Physiology, University of Yaounde 1, P.O. Box 812, Yaounde, Cameroon

Penlap Beng Véronique

Laboratory for tuberculosis research and pharmacology, Department of Biochemistry, Faculty of Science, University of Yaounde 1, P.O. Box 812, Yaounde, Cameroon

Correspondence:

1) Laboratory of Animal Physiology, Department of Animal Biology and Physiology, University of Yaounde 1, P.O. Box 812, Yaounde, Cameroon

2) Laboratory for Phytobiochemistry and Medicinal Plants Studies, Department of Biochemistry, Faculty of Science, University of Yaounde 1, P.O. Box 812, Yaounde, Cameroon

3) Centre for Research on Filariasis and Other Tropical Diseases, P.O.Box 5797 Yaounde, Cameroon

Email: [fotsingrace\[at\]yahoo.fr](mailto:fotsingrace[at]yahoo.fr)

Anti-inflammatory potential of *Tapinanthus globiferus* (Loranthaceae) leaves as an alternative treatment against arthritis

Gounoue Kamkumo Raceline*, Noukeu Kamta Bruno Aubin, Tsakem Nangap Marius Jaures, Youmsi Fokouo Ducos, Ngueguim Tsofack Florence, Dzeufiet Djomeni Paul Desire, Dimo Théophile, Penlap Beng Véronique

ABSTRACT

Rheumatoid arthritis is a systemic autoimmune inflammatory disease which treatment remains a challenge, due to adverse effects caused by conventional medicines. The study assesses the effects of aqueous extract of *Tapinanthus globiferus* leaves on complete Freund's adjuvant (CFA)-induced rheumatoid arthritis in rat. Rheumatoid arthritis was induced by inoculation of 0.1 mL of CFA under the plantar aponeurosis of rat. Animals were daily treated for 10 days with distilled water (10 mL/kg), sodium diclofenac (5 mg/kg) and aqueous extract of *T. globiferus* at doses of 50, 100 and 200 mg/kg. Healthy animals received distilled water (10 mL/kg). The volume of edema of the hind paw was measured using a plethysmometer. At the end of the treatment the animals were sacrificed, blood was collected for hematological and biochemical analyses. Some organs such as liver, kidney and tibiotarsal joint were used for biochemical and histological analyses. The administration of the aqueous extract of *T. globiferus* to diseased rats significantly alleviated physiological impairment by reducing of paw volume ($p < 0.001$), protecting animals from anemia ($p < 0.001$), leukocytosis ($p < 0.001$), transaminases activity increasing ($p < 0.001$), alkaline phosphatase ($p < 0.01$) and hypercreatininemia ($p < 0.001$). The plant extract has improved the antioxidant status of animals ($p < 0.001$) and the architectural organisation at joint level. The beneficial effects generated by the aqueous extract of *T. globiferus* leaves against the physiological dysfunctions caused by CFA justify its current use in the traditional treatment of rheumatoid arthritis.

Keywords: Rheumatoid arthritis, complete Freund's adjuvant, *Tapinanthus globiferus*, curative activity, acute toxicity.

INTRODUCTION

Rheumatoid arthritis (RA) is one of the commonest chronic and inflammatory autoimmune disorders, characterized by swelling of synovium of joints, with destruction of articular structures [1]. The global prevalence of RA is approximately 1% in worldwide population and women seem to be more sensitive than men [2]. The cause of RA is poorly known; however, initiation of disease could result from interaction among genetic susceptibility, environmental triggers and chance [3]. The disease is characterized by dysregulated inflammatory processes in the synovium of the joint that could lead to the damage of both cartilage and bone often resulting in motor disabilities [4]. RA is associated to a significant reduction in health-related quality of life and imposes a substantial economic burden to affected people, due to both increased cost of medical care and loss or reduction of employment for workers [5-7]. Conventional medicine to prevent clinical signs or progression of the disease consist of non-steroidal anti-inflammatory drugs, corticosteroids, biological therapies, immunosuppressive therapies and Disease Modifying Anti-Rheumatic Drugs (DMARDs) are commonly used; but side effects occurrence causes earlier treatment interruption that motive population to target natural products for relieving their illnesses. Preceding research asserted that people from developing countries mainly use natural resource for their healthcare needs, either for their efficiency, accessibility, affordability or sometimes their low toxicity [8].

Moreover, medicinal plants have been used for the treatment of several human diseases over the century and have been the source of some modern drugs [9]. Recent research has focused on natural plant product as alternatives to the existing drugs for disease remedy in developing countries [10]. The valorization of natural resources used for treatment could be pipeline to manage healthcare. *Tapinanthus globiferus* (*T. globiferus*) (Loranthaceae) is traditionally used against inflammatory diseases, malaria, bacterial infections, ulcers, headaches, diabetes mellitus, stroke, stomach problems, and seizures [11].

Previous studies have also demonstrated the antioxidant and nephroprotective properties of *T. globiferus* [12, 13]. In our knowledge, there is no scientific study on the anti-inflammatory activity of *T. globiferus* aqueous extract. The present study aims to evaluate effects of the aqueous extract of *T. globiferus* leaves in the complete Freund's adjuvant-induced arthritis in rat.

MATERIAL AND METHODS

Preparation of plant extract and phytochemical screening

The entire plant *Tapinanthus globiferus* (*T. globiferus*) (A. Rich.) Van Tiegh was harvested from *Persea americana* (avocado) in September 2017 in Yaounde, Centre Region- Cameroon and was authenticated by a botanist, Mr Nana Victor, at the National Herbarium of Cameroon in comparison with a voucher specimen deposited under N° 24672/SRFCam. Fresh leaves were collected from *T. globiferus* branches, dried in shade and crushed. The decoction was carried out by boiling 500 g of plant powdered in 5 L of distilled water for 20 minutes, following the healer instructions, then cooled at room temperature for 30 minutes. The mixture was filtered and the filtrate was lyophilised (yield approximately 17.53% w/w) then kept at room temperature until use. Phytochemical screening of extract was carried out according to standardized protocols in order to investigate the presence of some compounds such as flavonoids, saponins, tannins, phenols [14], steroids [15], triterpenes [16], glucosides, anthocyanins and alkaloids [17].

Animals

Three months old female Wistar rats weighing 170-190 g were used for the study. They were bred in the Animal House of the Faculty of Science, University of Yaounde I. Animals were reared in standard cages, at room temperature of 22 ± 2 °C on a 12 h light-dark natural cycle. Food and water were given *ad libitum* throughout the experiment. All experiments were carried out with approval of Institutional Ethical Committee, which adopted all procedures recommended by the European Union on the protection of animals used for scientific proposes (CEE Council 86/609; Ref N° FWA-IRD 0001954).

Acute oral toxicity study

Eight healthy female Wistar rats were subjected to acute oral toxicity studies using OECD (2001) guideline-423 [18] with slight modifications. Animals were fasted for 12 h, provided only with water. The aqueous extract of *Tapinanthus globiferus* was orally administered at single dose of 5000 mg/kg body weight to four animals, the four others receiving distilled water at 10 mL/kg. Then, animals were observed continuously for behavioural and autonomic profiles for 2 h and for any signs of toxicity or mortality up to 14 days.

Induction of rheumatoid arthritis in rats

Rheumatoid arthritis was induced by injection of single volume (0.1 mL) of complete Freund's adjuvant (CFA) (Sigma) under subplantar of the left hind paw of animal according to the protocol described by Fehrenbacher *et al.* [19].

Assessment of the effects of *T. globiferus* on CFA-induced arthritic in rat

Thirty (30) healthy female Wistar rats were used for the study. Rheumatoid arthritis was induced in 25 animals whereas 5 was kept unharmed and constituted normal control. After CFA injection, the animals were kept under breeding conditions for 8 days during which the arthritis development was followed as described by Young *et al.* [20] with slight modifications. On day 9, the animals were randomly divided into five groups of five animals each and treated as follow: group I (Normal control), without CFA injection receiving distilled water (10 mL/kg); group II (CFA-control), animal with arthritis and treated with distilled (10 mL/kg), group III (diclofenac control), animal with

arthritis receiving sodium diclofenac (5 mg/kg) as reference drug; group IV, V and VI (test groups) consisted of animal with arthritis and treated with 50, 100 and 200 mg/kg plant extract respectively. The extract dose has been given through the healer instructions. A single daily dose was orally administered for 10 days and the measurements of the edema of hind paw were recorded on days 0, 5, 9, 12, 15 and 18 post CFA injection using plethysmometer-Ugo-Basile 7141 apparatus (USA). Day zero (D0) was considered as the baseline of CFA injection.

The percentage of increase in paw edema was determined according to the following formula: % increase in paw oedema = $(T_1 - T_0/T_0) \times 100$.

Where, T_0 is the mean of paw thickness at day 0 and T_1 is the mean of paw thickness at a given time. The results were statistically compared to the CFA-control group.

Evaluation of the effects of aqueous extract of *T. globiferus* on physiological changes in animal

At the end of the experiment, animals were fasted for 12 hours then, anesthetized using ketamin (30 mg/kg) and diazepam (10 mg/kg) then sacrificed. Blood was collected through carotid artery in EDTA tubes for haematological analysis and in dry tubes which was centrifuged at 3000 rpm at 4°C for 15 minutes. The serum was collected and stored at -20°C for biochemical analysis. The liver, kidneys and tibiotarsal joint were removed and weighed. Portions of 0.4 g of liver and kidney were homogenized into 2 mL of Tris-HCl buffer (50 mM, pH = 7.4) and the joint into 2 mL of PBS (0.1 M, pH = 7.4) and then centrifuged at 3000 rpm at 4°C for 25 minutes. The supernatant obtained was stored at -20°C for the determination of some markers of oxidative stress. The tibiotarsal joint was fixed in 10% formalin for histological analysis.

Hematological and biochemical assesment

Some hematological parameters analysis such as red blood cells (RBC) count, white blood cells (WBC) count, platelets (PLT) count, haemoglobin (HGB) level and leucocytes species (lymphocytes (LYM), granulocytes (GRA) and monocytes (MON)) were done with total blood using the hematometer type "Hospitex Diagnostics Hema Screen 18". Biochemical analyses were focused on the total proteins according to the protocol of Gornall *et al.* [21], creatinine, alkaline phosphatase (APL), alanine aminotransferase (ALT) and aspartate aminotransferase (AST) level according to the protocols provided by Fortress Diagnostics commercial kits (UK). The supernatant collected from organ was used to investigate catalase [22], superoxide dismutase SOD [23], malondialdehyde (MDA) [24], and reduced glutathione (GSH) [25].

Histopathological analysis of tibiotarsal joint

The knee joints of the left hind legs were removed from the rats for histological analysis. The joints were fixed into 10% formalin, decalcified into Tris-EDTA solution for 24 days, and then embedded in paraffin. Serial paraffin sections at 5 µm were stained with hematoxylin and eosin (HE) for examination under light microscopy brand Olympus.

Statistical analysis

The results were expressed as mean \pm standard deviation (SD). The statistical analyses were performed using the Analysis Of Variance (ANOVA), followed by the Tukey post test using GraphPad Prism version 7.00 software. Values were considered significant for $p < 0.05$.

RESULTS AND DISCUSSION

Phytochemical screening of the aqueous extract of *Tapinanthus globiferus*

Qualitative phytochemical analysis of the aqueous extract of *Tapinanthus globiferus* leaves revealed the presence of alkaloids,

flavonoids, polyphenols, tannins, steroids and saponins. Anthocyanins, triterpenes and glycosides were absent.

Acute oral toxicity studies

No toxicity signs or death were recorded with the extract plant administration, indicating that the oral lethal dose-50 (LD₅₀) of the aqueous extract of *Tapinanthus globiferus* was greater than 5000 mg/kg.

Effects of aqueous extract of *T. globiferus* on paw edema of animals

Figure 1 shows the effects of aqueous extract of *T. globiferus* on edema of the left hind paw of animal. The injection of complete Freund's adjuvant to healthy female rats resulted to the development of paw edema after 8 days leading to a paw volume up to 117.65% compared to the normal control. The paw volume of the untreated group (CFA control) significantly increased (p < 0.001), compared to normal control. The daily administration of a single dose of the plant extract from day 9 at all the doses 50, 100 and 200 mg/kg triggered after three days of treatment (day 12), a significant decrease in the paw volume of animals by 28.01% (p < 0.001), 34.91% (p < 0.001), and 20.21% (p < 0.01) respectively compared to CFA control. The sodium diclofenac (5 mg/kg) used as reference drug, significantly reduced the paw volume by 25.18% (p < 0.001). This decrease of the paw volume was observed till the end of treatment (day 18) by 35.25%, 29% and 33.60% (p < 0.001) respectively at doses 50, 100 and 200 mg/kg of the aqueous extract while sodium diclofenac (5 mg/kg) exhibited a reduction of 40.54% (p < 0.001) compared to CFA control. No significant change was observed at day 18 between test groups.

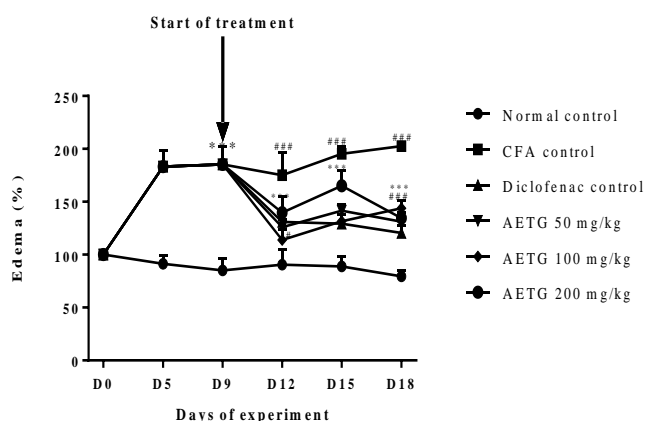


Figure 1: Effects of aqueous extract of *T. globiferus* in complete Freund's adjuvant-induced paw edema volume in rats.

Each point represents the mean ± SD, 5 ≤ n ≤ 25 from D0 to D9 and n = 5 after D9; #p < 0.05; ###p < 0.001: significant difference compared to normal control; **p < 0.01; ***p < 0.001: significant difference compared to CFA control; Normal control = healthy female rats treated with distilled water; CFA control = female arthritic rats treated with distilled water; Diclofenac control = female arthritic rats treated with sodium diclofenac (5 mg/kg); AETG 50, 100 and 200 = female arthritic rats treated with aqueous extract of *T. globiferus* at the respective doses of 50, 100 and 200 mg/kg.

Effects of the aqueous extract of *T. globiferus* in some hematological parameters in arthritic rats

The effects of aqueous extract of *T. globiferus* on some hematological parameters were summarized in Table I. It was noted that the complete Freund's adjuvant induced arthritis in the healthy female rats resulted at the end of the experiment to the increase of white blood cells count (WBC) by 134.40% (p < 0.01), lymphocytes (LYM) by 60.21% (p < 0.001), monocytes (MON) by 214.43% (p < 0.001), granulocytes (GRA) by 387.80% (p < 0.001) and platelets count (PLA) by 112.25% (p < 0.05) in the CFA control compared to the normal control. A significant decrease in red blood cell (RBC) count by 47.88% (p < 0.01) and hemoglobin rate (HGB) by 45.27% (p < 0.001) was observed in the CFA control compared to normal control. The daily administration of the plant extract at all the doses and sodium diclofenac (5 mg/kg) for 10 days induced a significant decrease in the WBC count (p < 0.001) at the extract doses of 50, 100 and 200 mg/kg and sodium diclofenac (5 mg/kg) (p < 0.01), compared to CFA control. In comparison to CFA control, a significant decrease in the lymphocytes count by 29.17% (p < 0.01), 48.62% (p < 0.001) and 52.44% (p < 0.001), 27.73% (p < 0.01), granulocytes by 66.63% (p < 0.001), 73.38% (p < 0.001), 74.71% (p < 0.001) and 74.63% (p < 0.001), was observed after treatment with extract respectively at the doses of 50, 100 and 200 mg/kg and sodium diclofenac (5 mg/kg). The proportion of the monocytes count was significantly decreased by 36.39% (p < 0.001) in the treatment of sodium diclofenac (5 mg/kg) and by 26.17% (p < 0.05) with plant extract treatment at the dose of 100 mg/kg compared to CFA control. The platelets count was significantly decreased by 78.99% (p < 0.001) and 65.16% (p < 0.01) with the extract at the doses 100 mg/kg and 200 mg/kg respectively compared to CFA control. As compared to CFA control, a significant increase in the red blood cells count by 115.60% (p < 0.001) and 68.12% (p < 0.05), in hemoglobin level by 58.25% (p < 0.05) and 51.20% (p < 0.05) was observed in animal treated with sodium diclofenac (5 mg/kg) and plant extract (200 mg/kg) respectively. No significant change was observed with others haematological parameters in experimental groups.

Table 1: Effects of aqueous extract of *T. globiferus* on some hematological parameters in CFA-induced arthritis in rats

Parameters	Experimental group of animals					
	Normal control	CFA control	Diclofenac control	AETG 50	AETG 100	AETG 200
WBC (10 ³ /mm ³)	9.73±0.27	22.82±10.06##	10.33±0.82**	7.63±2.19***	8.34±3.13***	8.50±3.80***
LYM (10 ³ /mm ³)	55.96±2.04	89.65±9.29###	64.79±15.94**	63.49±13.22**	46.06±2.36***	42.63±1.00***
MON (10 ³ /mm ³)	6.83± 0.48	21.46±3.72###	13.65±1.79***	17.03±1.89	15.84±0.47*	22.82± 4.26
GRA (10 ³ /mm ³)	12.3±8.71	60.00±11.87###	15.23±4.42***	20.03±11.81***	15.98±6.69***	15.18±7.04***
PLA (10 ³ /mm ³)	417.67±21.92	886.5±39.12#	570.16±16.71	495.94±10.09	186.25±25.16***	308.81±25.97**
GR (10 ⁶ /mm ³)	8.38±1.21	4.37±0.38##	9.41±2.10***	5.77±1.28	4.41±1.83	7.34±0.68*
HGB (g/dl)	15.68±3.13	8.58±0.81###	13.58±2.44*	10.75±3.34	11.7±1.37	12.98±0.84*

Each value represents the mean ± SD, n = 5; #p < 0.05; ##p < 0.01; ###p < 0.001: significant difference compared to normal control; *p < 0.05; ** p < 0.01; ***p < 0.001: significant difference compared to CFA control; Normal control = healthy female rats treated with distilled water; CFA control = female arthritic rats treated with distilled water; Diclofenac control = female arthritic rats treated with sodium diclofenac (5 mg/kg); AETG 50, 100 and 200 = female arthritic rats treated with aqueous extract of *T. globiferus* at the respective doses of 50, 100 and 200 mg/kg.

Effects of aqueous extract of *T. globiferus* in the creatinine level in CFA-induced arthritis in rat

Figure 2 illustrates the effects of aqueous extract of *T. globiferus* creatinine level in animals with arthritis. A single injection of CFA in paw significant increased the creatinine levels ($p < 0.001$) in CFA control compared to normal control. The daily single treatment with aqueous extract of *T. globiferus* at the doses of 50, 100 and 200 mg/kg and sodium diclofenac (5 mg/kg) significantly induced a decrease in creatinine levels by 45.23%, 51.65% and 55.65% and 46.81% ($p < 0.001$) compared to CFA control. No difference in creatinine levels was noted between groups of animals treated with plant extract and the diclofenac control group.

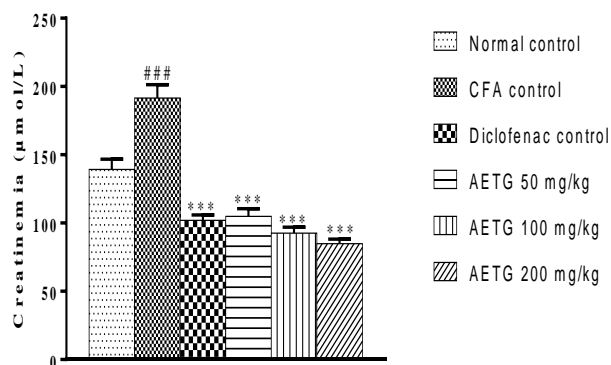


Figure 2: Effects of aqueous extract of *T. globiferus* on the creatinine levels in arthritis rats.

Each bar represents the mean \pm SD, $n = 5$; ### $p < 0.001$: significant difference compared to the normal control; *** $p < 0.001$: significant difference compared to the CFA control; Normal control = healthy female rats treated with distilled water; CFA control = female arthritic rats treated with distilled water; Diclofenac control = female arthritic rats treated with sodium diclofenac (5 mg/kg); AETG 50, 100 and 200 = female arthritic rats treated with aqueous extract of *T. globiferus* at the respective doses of 50, 100 and 200 mg/kg.

Effects of aqueous extract of *T. globiferus* on transaminase activities in CFA-induced arthritis in rats

The effects of aqueous extract of *T. globiferus* on transaminase activity (ALT and AST) into the animals with arthritis are presented in Figure 3. It was observed that animals receiving a single dose of CFA and untreated showed a significant increase of the AST and ALT activity by 25.13% and 65.78% ($p < 0.001$) respectively compared to the normal control. In comparison to the CFA control, the daily administration of the aqueous extract of *T. globiferus* leaves (50, 100 and 200 mg/kg) and sodium diclofenac (5 mg/kg) for 10 days led to a significant decrease in the activity of those enzymes by 46.96%, 36.97%, 45.60% for AST ($p < 0.001$) and 35.70%, 35.55%, and 35.93% for ALT ($p < 0.001$) respectively. The diclofenac (5 mg/kg) induced a significant ($p < 0.001$) decrease in the AST and ALT activities respectively by 35.36% and 29.61%. No change in transaminase activity was observed between the test animal groups and the Diclofenac (5 mg/kg) control.

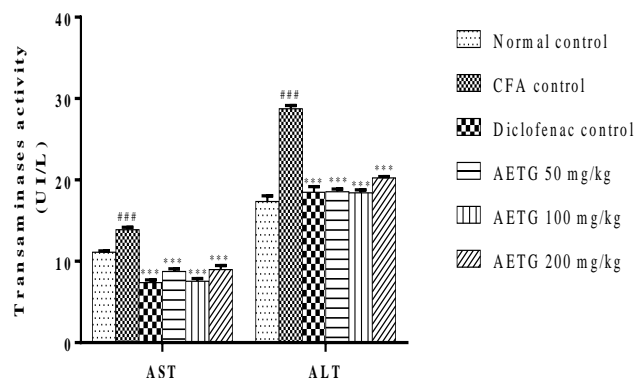


Figure 3: Effects of aqueous extract of *T. globiferus* on the activity of transaminases (ALT and AST) in CFA-induced arthritis in rats.

Each bar represents the mean \pm SD, $n = 5$; ### $p < 0.001$ = significant difference compared to the normal control; *** $p < 0.001$: significant difference compared to CFA control; Normal control = healthy female rats treated with distilled water; CFA control = female arthritic rats treated with distilled water; Diclofenac control = female arthritic rats treated with sodium diclofenac (5 mg/kg); AETG 50, 100 and 200 = female arthritic rats treated with aqueous extract of *T. globiferus* at the respective doses of 50, 100 and 200 mg/kg.

Effects of aqueous extract of *T. globiferus* in the alkaline phosphatase (APL) activity in rat

The induction of rheumatoid arthritis by CFA-injection in paw hind of animals resulted after 18 days to a significant increase in APL activity by 40.59% ($p < 0.01$) in the CFA control compared to the normal control (Figure 4). The daily administration of the aqueous extract of *T. globiferus* leaves (50 mg/kg) and sodium diclofenac (5 mg/kg) induced in animals a significant decrease in the activity of the enzyme respectively by 22.38% ($p < 0.01$) and 19.10% ($p < 0.05$) in comparison to the CFA control. There was a non-significant decrease in ALP activity at the doses of 100-200 mg/kg of the plant extract.

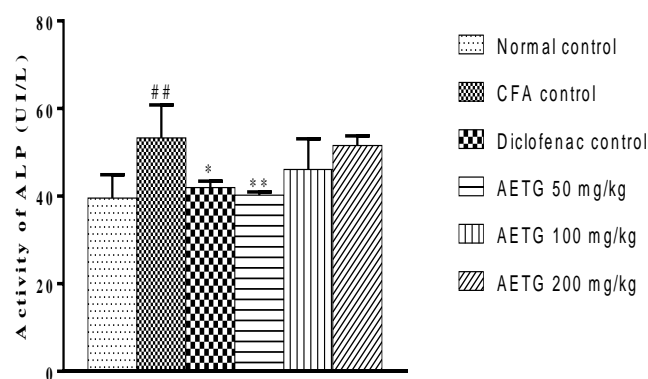


Figure 4: Effects of aqueous extract of *T. globiferus* on the activity of alkaline phosphatase.

Each bar represents the mean \pm SD, n = 5; ##p < 0.01: significant difference compared to normal control; *p < 0.05; **p < 0.01: significant difference compared to CFA control; Normal control = healthy female rats treated with distilled water; CFA control = female arthritic rats treated with distilled water; Diclofenac control = female arthritic rats treated with sodium diclofenac (5 mg/kg); AETG 50, 100 and 200 = female arthritic rats treated with aqueous extract of *T. globiferus* at the respective doses of 50, 100 and 200 mg/kg.

Effects of aqueous extract of *T. globiferus* leaves on some oxidative stress parameters in CFA-induced arthritis in rats

The effects of *T. globiferus* leaves extract on some oxidative stress parameters in CFA-induced arthritis in rats are summarized in Figure 5. A single dose injection of CFA into the paw hind of animals induced after 18 days a significant decrease of catalase activity by 39.50% (p < 0.01) in the liver, 35.18% (p < 0.05) in the kidney and a significant increase by 248.37% (p < 0.001) in the tibiotarsal joint compared to the normal control (Figure 5A). The daily administration of *T. globiferus* extract at the doses of 100 and 200 mg/kg and sodium diclofenac (5 mg/kg), for 10 days induced a significant increase in hepatic catalase activity respectively by 87.96% (p < 0.001), 57.46% (p < 0.05) and 64.47% (p < 0.01) compared to the CFA control. A significant increase in renal catalase activity (p < 0.001) was observed with plant extract at doses of 50 and 200 mg/kg and sodium diclofenac (5 mg/kg) compared to CFA control. In the tibiotarsal joint, the extract (200 mg/kg) and sodium diclofenac (5 mg/kg) induced a significant increase in catalase activity (p < 0.01) by 170.86% and 43.44 % respectively compared to CFA control. The activity of catalase in the kidney and tibiotarsal joints of animals treated with the extract (200 mg/kg) has significantly increased by 228.41% (p < 0.001) and 844.03% (p < 0.01) respectively compared to the normal control.

In SOD analysis, the CFA injection has also provoked a significant decrease in SOD activity by 54.58% (p < 0.05) in the liver, 59.50% (p < 0.001) in the kidney and 48.95% (p < 0.001) in tibiotarsal joint in the CFA control in comparison to the normal control (Figure 5B). The plant extract administration resulted in a significant increase in hepatic SOD

activity at the dose of 200 mg/kg by 185.6% (p < 0.001) and sodium diclofenac (5 mg/kg) by 106.67% (p < 0.05) compared to CFA control. The extract at the doses of 50, 100 and 200 mg/kg and sodium diclofenac (5 mg/kg) significantly increased the SOD activity by 134.95% (p < 0.001), 113.27% (p < 0.01), 166.84% (p < 0.001) and 158.16% (p < 0.001) in kidney respectively and by 190.70%, 170.25%, 120.04% and 140.50% (p < 0.001) in the tibiotarsal joint tissue compared to CFA control. No significant change was observed between test and diclofenac groups.

The investigation of glutathione concentration showed a significant reduction by 42.01% (p < 0.01) in the liver, 40.77% (p < 0.01) in the kidney and 87.56% (p < 0.001) in joint in CFA control compared to the normal control (Figure 5C). Daily administration of *T. globiferus* extract for 10 days at the doses of 50, 100 and 200 mg/kg significantly increased the hepatic glutathione levels (p < 0.05) compared to the CFA control. In the kidney, a significant increase in the GSH level by 62.01% (p < 0.001) and 44.46% (p < 0.05) was observed in the animals treated with the extract at the dose of 200 mg/kg and sodium diclofenac (5 mg/kg) respectively compared to the CFA control. The treatment of arthritic animals with aqueous extract of *T. globiferus* at 100 mg/kg and sodium diclofenac (5 mg/kg) induced a significant increase in GSH in the joint by 90.12% (p < 0.01) and 92.92% (p < 0.001) compared to the CFA control. Figure 5D shows a significant increase in MDA by 40.15% (p < 0.001) in the liver, 81.86% (p < 0.001) in the kidney and 31.41% (p < 0.05) in tibiotarsal joint of CFA control as compared to the normal group. In comparison with the CFA control, the plant extract at the doses of 50, 100 and 200 mg/kg induced a significant decrease in MDA level in the liver by 24.69% (p < 0.001), 22.22% (p < 0.001) and 16.99% (p < 0.01), and in the kidney by 44.49%, 35.07% and 38.45% (p < 0.001) respectively. In the articular tissue, the plant extract at the doses of 100 and 200 mg/kg has significantly inhibited the MDA level increasing respectively by 33.30% (p < 0.01) and 30.50% (p < 0.01) compared to the CFA control. Sodium diclofenac (5 mg/kg) induced a significant decrease of MDA level by 39.89% (p < 0.001) in the liver, 40.51% (p < 0.001) in the kidney and 22.40% (p < 0.05) in the joint compared to the CFA control.

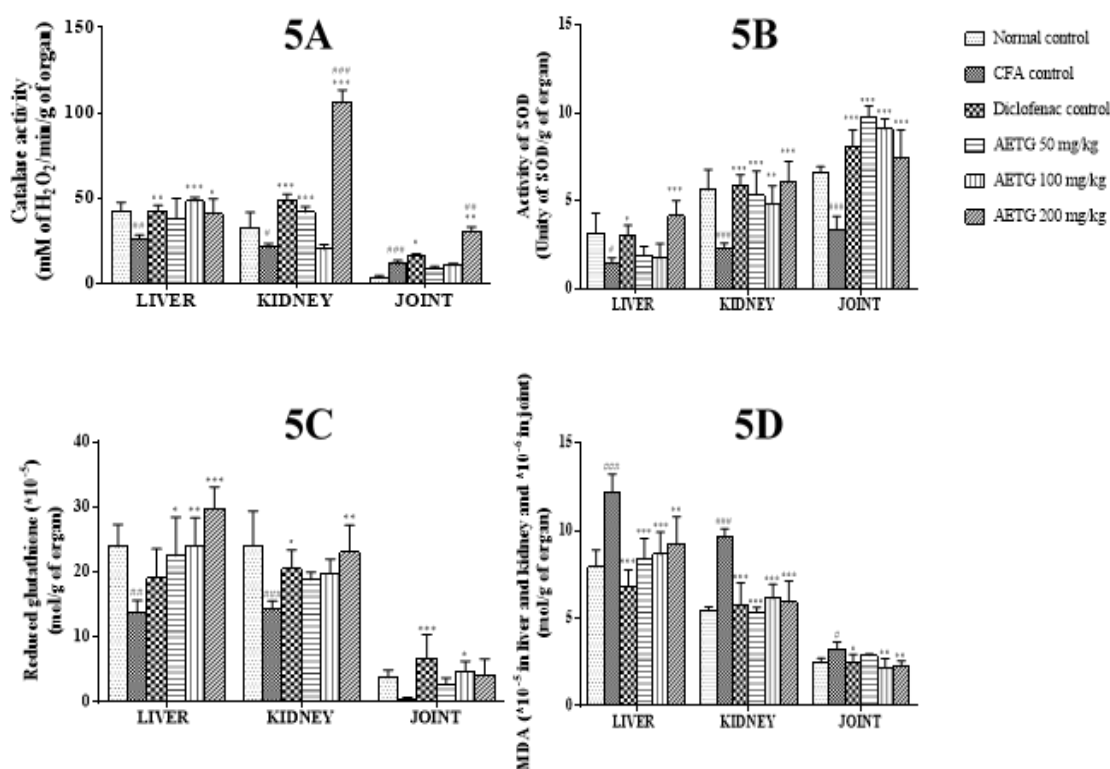


Figure 5: Effects of aqueous extract of *T. globiferus* in catalase (A), SOD (B), GSH (C), MDA (D) in liver, kidney and joint of CFA-induced arthritis rats

Each bar represents the mean ± SD, n = 5; ##p < 0.01; ###p < 0.001: significant difference compared to normal control; *p < 0.05; **p < 0.01: significant difference compared to CFA control; Normal control = healthy female rats treated with distilled water; CFA control = female arthritic rats treated with distilled water; Diclofenac control = female arthritic rats treated with sodium diclofenac (5 mg/kg); AETG 50, 100 and 200 = female arthritic rats treated with aqueous extract of *T. globiferus* at the respective doses of 50, 100 and 200 mg/kg.

Effects of aqueous extract of *T. globiferus* on protein concentration in animal with arthritis

In the CFA control, a significant increase of total serum protein by 24.56% (p < 0.001) was observed compared to normal control (Figure 6). The administration of the aqueous extract of *T. globiferus* at the doses of 50 and 100 mg/kg induced a significant decrease in the serum protein levels (p < 0.01) in comparison to the CFA control. A significant increase in total protein levels by 16.69% (p < 0.01) and 31.28% (p < 0.01) was observed in the liver and kidney respectively, in CFA control in comparison to the normal control. The treatment of arthritic animals with plant extract has provoked a significant decrease of total protein (p < 0.01) in the liver at the dose of 50 mg/kg and in the kidney (p < 0.05) at the dose of 200 mg/kg compared to the CFA control. A significant decrease of proteins by 13.23% (p < 0.05) in serum, 12.07% (p < 0.05) in the liver and 39.29% (p < 0.001) in the kidney was recorded in diclofenac control compared to the CFA control. No significant changes in serum total protein and in liver and kidney protein levels was observed between the animals treated with the extract (50 mg/kg) and the normal control group.

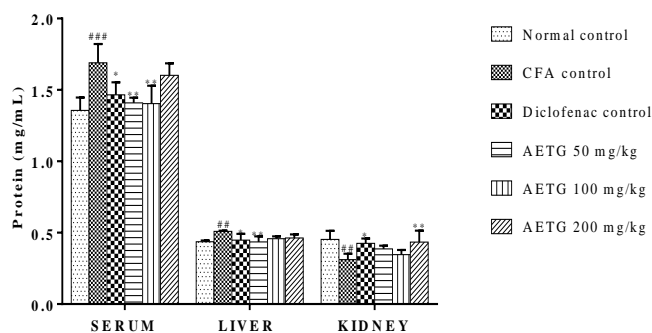


Figure 6: Effects of aqueous extract of *T. globiferus* in serum, hepatic and renal protein levels.

Each bar represents the mean ± SD, n = 5; ##p < 0.01; ###p < 0.001: significant difference compared to normal control; *p < 0.05; **p < 0.01: significant difference compared to CFA control; Normal control = healthy female rats treated with distilled water; CFA control = female arthritic rats treated with distilled water; Diclofenac control = female arthritic rats treated with sodium diclofenac (5 mg/kg); AETG 50, 100 and 200 = female arthritic rats treated with aqueous extract of *T. globiferus* at the respective doses of 50, 100 and 200 mg/kg.

Effects of *T. globiferus* aqueous extract on histological changes in tibiotarsal joint

Figure 7 shows the effects of plant extract in tibiotarsal joint tissue of arthritic animals. The histology of the normal tibio-tarsal joint presents a normal architecture with regular articular cartilage (AC) and differentiated chondrocytes (Chd) in the head of bones. Injection of CFA under the animal's plantar aponevrosis induced an alteration with paw edema, characterized by inflammation, exudate, and a colored paw. Micrographical analysis shows an inflammation in the cartilage (CI), degenerated chondrocytes (DC) and inflammatory cells (IC). The administration of the aqueous extract of *T. globiferus* at 50 mg/kg partially improved the tissue architecture in which both altered and normal chondrocytes are observed. The treatment with sodium diclofenac (5 mg/kg) or aqueous extract of *T. globiferus* (100 mg/kg)

has restored the normal architecture in the tibiotarsal joint of animal as similar to the normal control.

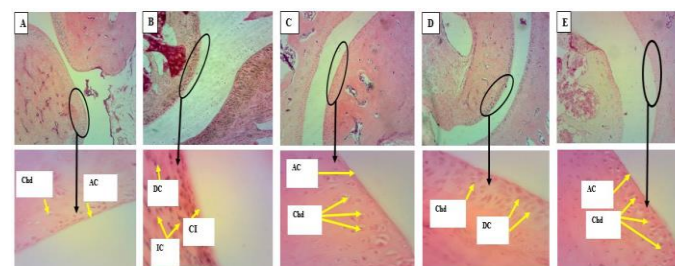


Figure 7: Effects of aqueous extract of *T. globiferus* on histological changes in the tibiotarsal joint of the left hind paw in normal control (A), CFA control (B), diclofenac control (C), AETG 50 mg/kg (D) and 100 mg/kg (E) (Hematoxylin-Eosine 40x (top) and 200x (bottom)).

Normal control = healthy female rats treated with distilled water; CFA control = female arthritic rats treated with distilled water; Diclofenac control = female arthritic rats treated with sodium diclofenac (5 mg/kg); AETG 50, 100 and 200 = female arthritic rats treated with aqueous extract of *T. globiferus* at the respective doses of 50, 100 and 200 mg/kg. Chd = chondrocytes; AC = articular cartilage; DC = degenerate chondrocytes; CI = cartilage inflammation; IC = inflammatory cells.

DISCUSSION

The present study aimed to evaluate the anti-arthritis effects of the aqueous extract of *Tapinanthus globiferus* leaves in the CFA-induced rheumatoid arthritis (RA) in Wistar female rat. The CFA induction model is characterized by an inflammation involving complex systemic changes resulting in a synovial inflammation and joint damage, which are some common clinical signs associated to sustain the increase in posterior paw volume of animals as observed in the study. This pathological condition include an excessive production of pro-inflammatory and inflammatory mediators that increase vascular permeability [26, 27] and release an important reactive oxygen species [28, 29]. The significant decrease in paw volume of animal after *Tapinanthus globiferus* extract administration indicated an anti-inflammatory activity of the extract expressing through certain phenolic compounds acting by inhibition of the release and/or the activation pathway of histamine, prostaglandins and proinflammatory cytokines implicated in the inflammation [30, 31]. A clinical sign of RA is anemia due to Tumor Necrosis Factor-α (TNF-α), interferon γ (INF γ) and interleukin-1 (IL-1) activity, that act by inhibition of the Colony-Forming Unit-Erythrocytic (CFU-E) and, the biological activity of erythropoietin resulting in hypochromic anemia [32, 33]. The antianemic effect of the *T. globiferus* extract could result from alkaloids and tannins activity which provoke a reduction in TNF-α and IFN-γ plasma level [34], while the tannins induce a downregulation of TNF-α [35]. The increase in the white blood cells counts and leucocyte species (lymphocytes, monocytes and granulocytes) and platelets count recorded in the study, in CFA-induced arthritis is well described as a pathogenesis of rheumatoid arthritis [36]. The mechanism of pathogenesis include an increase of the production in free radicals by the interleukins-activated granulocytes [37]. A significant decrease in leucocytes count obtained after plant extract treatment, could express an immunomodulatory activity of tannins and flavonoids that are able to scavenge body from reactive oxygen species [34, 35, 38].

The increase in platelet counts observed during RA could be due to the production of inflammatory cytokines such as IL-1, IL-6 and TNF [39]. Treatment with *T. globiferus* extract resulted in a significant decrease in platelet counts suggesting its involvement in downregulation of IL-1 and TNF-α across tannins content [35].

The transaminase activity (AST, ALT), alkaline phosphatase (ALP) and serum creatinine concentration measurement are a targeted tools to assess antiarthritic activity of promising drug [40, 41]. The significant increase in the activity of these enzymes (AST, ALT and ALP) and

creatinine concentration observed in animals with arthritis demonstrates the destroyed effects of CFA in liver cells expressing by significant release of transaminases and ALP, in kidney by renal cells necrosis that result in to glomerular filtration impairment [42, 43] and in bone which involves localized bone loss in form of periarticular erosion and osteopenia, as the enzyme released into the circulation during bone formation and resorption [37]. CFA-induced arthritis is associated with release of inflammatory mediators such as superoxide and hydrogen peroxide produced by activated leucocytes. Those free radicals cause cellular disruption through peroxidation of membrane lipids [44]. Activated oxygen intermediates together with secondarily formed hydroxyl radicals (HO[•]) damage lipids membrane, proteins and cartilage [45]. In the present study, these observations were supported by the significant increase of malondialdehyde (MDA) in the liver, kidney and joint in CFA control group. The enhancement in MDA levels suggests an increase in lipid peroxidation leading to the destruction of organs. The reduction in antioxidant defenses (superoxide dismutase (SOD), catalase (CAT) and reduced glutathione (GSH)) could be a consequence of their neutralizing effects to reactive oxygen species (ROS) [46]. The administration of *T. globiferus* extract whatever the dose has prevented the decrease in these enzymes, suggesting the antioxidant property of the extract. Thus, the extract could be able to protect organs against free radicals and/or trap them after their generation, restoring the balance prooxidant/antioxidant [47]. Flavonoids through their ability to trap free radicals [46], as well as the regulatory function of tannins [35] and alkaloids [34] on proinflammatory cytokines would be responsible for the hepatoprotective, nephroprotective and osteoprotective effects of the aqueous extract of *T. globiferus*.

In our study, CFA-induced arthritis is associated with a significant increase in the paw volume of the arthritic rats compared to the normal which showed impairment in the joint structure with degenerate chondrocytes, cartilage inflammation and prominent leucocytic inflammatory cells as observed in the micrography of the tibiotarsal joint of arthritic animals. AETG administration to arthritic rats showed significant reduction in the paw inflammation with an architecture close to the normal rat at the extract dose of 100 mg/kg. These results indicate anti-inflammatory property of the extract which could exert through the bioactive metabolites such as flavonoids, alkaloids, and tannins present in the *T. globiferus* extract with antioxidant and immunomodulatory activity. In addition to free radical scavenging activity, flavonoids are involved in the effective reduction of NO (nitric oxide), TNF- α [46] and have immunomodulatory role [38]. Alkaloids act by reducing plasma levels of TNF- α , interferon- γ (IFN- γ) (macrophage activator) and NO [34]. Tannins are responsible for downregulation in TNF- α and IL-6, which mediate the recruitment of immune cells and stimulate the increase of ROS [35]. Thus these groups of compound act synergically to counteract CFA-induced adverse effects.

Finally, the acute toxicity study of the aqueous extract of *T. globiferus* revealed no signs of toxicity or death in animals after 14 days of experimentation at the dose of 5000 mg/kg, suggesting that the lethal dose 50 (LD₅₀) of the extract is greater than 5000 mg/kg with classification as less or not toxic substance according to the Globally Harmonized Classification System (GHS) [18]. This result was also reported by Abubakar *et al.* [11] showing that the LD₅₀ of the aqueous extract of *T. globiferus* is greater than 5000 mg/kg in chicks and mice.

CONCLUSION

The general objective of this study was to evaluate the anti-arthritic activity of the aqueous extract of *Tapinanthus globiferus* leaves on rheumatoid arthritis induced in female Wistar rats by complete Freund's adjuvant. Oral daily administration extract for 10 days reduced edema of the animal's paw, protected from anemia, leukocytosis, hypercreatininemia and hyperactivity of transaminases (AST and ALT), restored the antioxidant status and also protected against architectural damage at the joint level. These results showed that the extract would have anti-inflammatory, immunomodulatory, antioxidant, osteoprotective and hepato-nephroprotective properties,

which would be due to bioactive metabolites such as alkaloids, flavonoids, polyphenols and tannins present in the extract. The LD₅₀ of the extract is greater than 5000 mg/kg. These beneficial properties of the extract observed in the present study justify the traditional use of aqueous extract of *T. globiferus* leaves in the treatment of rheumatoid arthritis.

ACKNOWLEDGEMENTS

The authors are grateful to Mr Nana Victor at the Cameroon National Herbarium for the authentication of the plant species, the "Pathologie Cytologie Développement" team through Mrs Catherine Cannet and Nathalie Accart for histological analyses.

REFERENCES

1. Firestein GS. Evolving concepts of rheumatoid arthritis. *Nature* 2003; 423:356.
2. Langford CA, Fauci AS. Harrison's rheumatology. 4th ed. New York, United states: McGraw-Hill Education, 2017.
3. Gibofsky A. Epidemiology, pathophysiology, and diagnosis of rheumatoid arthritis: a synopsis. *Am. J. Manag. Care.* 2014; 20:S128-35.
4. Mbiantcha M, Almas J, Shabana SU, Nida D, Aisha F. Anti-arthritic property of crude extracts of *Piptadeniastrum africanum* (Mimosaceae) in complete Freund's adjuvant-induced arthritis in rats. *BMC Complement. Altern. Med.* 2017; 17:1-16.
5. Dominick KL, Ahern FM, Gold CH, Heller DA. Health-related quality of life among older adults with arthritis. *Health Qual. Life. Outcomes*, 2004; 2:5.
6. Huelsemann JL, Mittendorf T, Merkesdal S, Zeh S, Handelmann S, von der Schulenburg J, *et al.* Direct costs related to rheumatoid arthritis: the patient perspective. *Ann. Rheum. Dis.* 2005; 64:1456-1461.
7. Sokka T, Kautiainen H, Pincus T, Verstappen SMM, Aggarwal A, Alten R, *et al.* Work disability remains a major problem in rheumatoid arthritis in the 2000s: data from 32 countries in the QUEST-RA study. *Arthritis Res. Ther.* 2010; 12:R42.
8. Barnes PM, Bloom B, Nahin RL. Complementary and alternative medicine use among adults and children; United States, 2007. *Natl. Health Stat. Report*, 2008; 10:1-23.
9. Oluma HO, Umeh EU, Onekutu A, Okolo J. Antibacterial potentials of eight medicinal plants from the lower Benue valley of Nigeria. *Nig. J. Bot.* 2004; 17:1-11.
10. Aiyegoro OA, Akinpelu DA, Okoh AI. *In vitro* antibacterial potentials of the stem bark of red water tree (*Erythrophloeum suaveolens*). *J. Biol. Sci.* 2007; 7:1233-1238.
11. Abubakar K, Adebisi I, Ugwah-oguejiofor J, Idris G, Idris B, Mshelia H. Phytochemical screening and anticonvulsant activity of the residual aqueous fraction of *Tapinanthus globiferus* growing on *Ficus glums*. *Herb. Med.* 2016;2:1-6.
12. Ogunbolude Y, Ibrahim M, Elekofehinti OO, Adeniran A, Abolaji AO, Rocha JB, *et al.* Effects of *Tapinanthus globiferus* and *Zanthoxylum zanthoxyloides* extracts on human leukocytes in vitro. *J. Intercult. Ethnopharmacol.* 2014; 3:167-172.
13. Adekunle AS, Oyewo BE, Afolabi OK. Therapeutic efficacy of *Tapinanthus globiferus* on acetaminophen induced nephrotoxicity, inflammatory reactions and oxidative stress in albino rats. *Int. Res. J. Biosci. Biochem. Bioinforma.* 2012; 2:41-45.
14. Harborne JB. *Phytochemical methods: a guide to modern techniques of plant analysis.* London: Chapman and Hall, 1976.
15. Sofowara A. *Medicinal plants and traditional medicine in Africa.* 2nd ed. Nigeria: Limited Ibadan, 1993.
16. Evans WC, Trease GE. *Trease and Evans' pharmacognosy.* 13th ed. London; Philadelphia: Bailliere Tindall, 1989.
17. Odebiyi O, Sofowora E. Antimicrobial alkaloids from a nigerian chewing stick (*Fagara zanthoxyloides*). *J. Med. Plant. Res.* 1979; 36:204-207.
18. OECD. *Guideline for testing of chemical. Acute oral toxicity - acute toxic class method.* Paris: OECD, 2001.
19. Fehrenbacher JC, Vasko MR, Duarte DB. Models of Inflammation: Carrageenan or complete Freund's adjuvant (CFA)-induced edema and hypersensitivity in the rat. *Curr Protoc. Pharmacol.* 2012; 56:541-547.
20. Young DA, Hegen M, Ling H, Ma M, Whitters MJ, Albert LM, *et al.* Blockade of the interleukin-21/interleukin-21 receptor pathway ameliorates disease in animal models of rheumatoid arthritis. *Arthritis Rheum.* 2007; 56:1152-1163.
21. Gornall A, Bradwill C, David M. Determination of serum proteins by means of the biuret reaction. *J. Biol. Chem.* 1949; 77:167-182.
22. Sinha K. Colorimetric assay of catalase. *Anal. Biochem.* 1972; 47:389-394.

23. Misra H, Fridovich I. Determination of the level of superoxide dismutase in whole blood. *Yale University Press New Haven*, 1972; 101-109.
24. Wilbur K, Bernhein F, Shapiro O. Determination of lipid peroxydation. *Arch. Biochem. Biophys.* 1949; 24:3959-3964.
25. Ellman G. Tissue sulfhydryl group. *Arch. Biochem. Biophys.* 1959; 82:70-77.
26. Prajapati DS, Shah JS, Sen DJ. Modulatory effect of telmisartan on anti-inflammatory effect of rosiglitazone in adjuvant arthritis model. *Int. J. Res. Pharm. Biomed. Sci.* 2011; 2:554-66.
27. Copstead-Kirkhorn LEC, Banasik JL. *Pathophysiology*. 5th ed. Amsterdam, Netherlands: Elsevier Health Sciences, 2013.
28. Cascão R, Vidal B, Raquel H, Neves-Costa A, Figueiredo N, Gupta V, *et al.* Potent anti-inflammatory and antiproliferative effects of gambogic acid in a rat model of antigen-induced arthritis. *Mediators Inflamm.* 2014; 2014:1-7.
29. Mahdi HJ, Khan NAK, Asmawi MZ Bin, Mahmud R, Vikneswaran A, Murugaiyah L. *In vivo* anti-arthritis and anti-nociceptive effects of ethanol extract of *Moringa oleifera* leaves on complete Freund's adjuvant (CFA)-induced arthritis in rats. *Integr. Med. Res.* 2018; 7:85-94.
30. Fotio A, Dimo T, Nguetefack T, Dzeufiet P, Ngo Lemba E, Temdie R, *et al.* Acute and chronic anti-inflammatory properties of the stem bark aqueous and methanol extracts of *Sclerocarya birrea* (Anacardiaceae). *Inflammopharmacology*, 2009; 17:229-237.
31. Arulselvan P, Tan W, Gothai S, Muniandy K, Fakurazi S, Esa N, *et al.* Anti-inflammatory potential of ethyl acetate fraction of *Moringa oleifera* in downregulating the NF- κ B signaling pathway in lipopolysaccharide-stimulated macrophages. *Molecules*. 2016; 21:1452.
32. Wick M, Pinggera W, Lehmann P. *Clinical aspects and laboratory. Iron metabolism, anemias: concepts in the anemias of malignancies and renal and rheumatoid diseases.* Vienna: Springer, 2012.
33. Firestein GS, Budd R, Gabriel SE, McInnes IB, O'Dell JR. Kelley and Firestein's Textbook of rheumatology. 10th ed. Amsterdam, London (Netherlands): Elsevier Health Sciences, 2017.
34. Li F, Wang H, Lu D, Wang Y, Qi R, Fu Y, *et al.* Neutral sulfate berberine modulates cytokine secretion and increases survival in endotoxemic mice. *Acta Pharmacol. Sin.* 2006; 27:1199-1205.
35. Reddy DB, Reddanna P. Chebulagic acid (CA) attenuates LPS-induced inflammation by suppressing NF- κ B and MAPK activation in RAW 264.7 macrophages. *Biochem. Biophys. Res. Commun.* 2009; 381:112-117.
36. Choy E. Understanding the dynamics: pathways involved in the pathogenesis of rheumatoid arthritis. *Rheumatology (Oxford, England)* 2012; 51:3-11.
37. Nandhagopal K, Kanniyakumari M. Effect on the biochemical and hematological parameters on *Rasa Mezugu* in Freund's adjuvant-induced arthritis rats. *World J. Pharm. Sci.* 2016; 4:81-85.
38. Akbay P, Basaran AA, Undeger U, Basaran N. *In vitro* immunomodulatory activity of flavonoid glycosides from *Urtica dioica* L. *Phytother. Res.* 2003;17:34-37.
39. Ertenli I, Kiraz S, Ozturk MA, Haznedaroglu IC, Celik I, Calguneri M. Pathologic thrombopoiesis of rheumatoid arthritis. *Rheumatol. Int.* 2003; 23:49-60.
40. Babu NP, Pandikumar P, Ignacimuthu S. Lysosomal membrane stabilization and anti-inflammatory activity of *Clerodendrum phlomidis* Lf, a traditional medicinal plant. *J. Ethnopharmacol.* 2011; 135:779-785.
41. Reddy VJS, Rao PGD, Lakshmi GR. A review on anti-arthritis activity of some medicinal plants. *Journal of Global Trends in Pharmaceutical Sciences.* 2014; 5:2061-2073.
42. Marshall WJ, Bangert SK, Raynaud E. *Biochimie médicale: physiopathologie et diagnostic.* Amsterdam, London (Netherlands): Elsevier, 2005.
43. Murphy MJ, Gaw A, Cowan RA. *Biochimie Clinique: Campus Illustre.* Amsterdam, London (Netherlands): Elsevier, 2004.
44. Devi PR, Kumari SK, Kokilavani C. Effect of *Vitex negundo* leaf extract on the free radicals scavengers in complete Freund's adjuvant induced arthritis rats. *Indian. J. Clin. Biochem.* 2007; 22:143-147.
45. Ricciotti E, FitzGerald GA. Prostaglandins and inflammation. *Arterioscler. Thromb. Vasc. Biol.* 2011; 31:986-1000.
46. Shafie M, Forghani A, Moshtaghiyan J. Anti-inflammatory effects of hydro-alcoholic extracts of Mangrove (*Avicennia marina*) and vitamin C on arthritic rats. *Bull. Env. Pharmacol. Life Sci.* 2013; 2:32-37.
47. Weydert CJ, Cullen JJ. Measurement of superoxide dismutase, catalase, and glutathione peroxidase in cultured cells and tissue. *Nat. Protoc.* 2010; 5:51-66.

HOW TO CITE THIS ARTICLE

Raceline GK, Aubin NKB, Jaures TNM, Ducos YF, Florence NT, Desire DDP, *et al.* Anti-inflammatory potential of *Tapinanthus globiferus* (Loranthaceae) leaves as an alternative treatment against arthritis. *J Phytopharmacol* 2019; 8(3):96-103.